



Case Series of Cutaneous Adnexal Tumours; a Voice to the Existing Literatures, a Tertiary Hospital Experience in South-South Nigeria

E. Imasogie Dele^{1*} and T. Azeke Akhator²

¹Department of Morbid Anatomy, University of Benin Teaching Hospital, P.M.B. 1111, Ugbowo, Benin City, Edo State, Nigeria.

²Department of Anatomic Pathology, Irrua Specialist Teaching Hospital, Irrua, Nigeria.

Authors' contributions

This work was carried out in collaboration between both authors. Author EID designed the study, co-managed the literature searches, performed the statistical analysis, co-wrote the protocol and wrote the first draft of the manuscript. Author TAA co-managed the analyses of the study, co-managed the literature searches and co- wrote the protocol. Both authors read and approved the final manuscript.

Article Information

DOI: 10.9734/JAMMR/2018/40650

Editor(s):

(1) Atanas Baltadjiev, Associate Professor, Department of Anatomy, Histology and Embryology, Medical University in Bulgaria, Bulgaria.

Reviewers:

(1) Renshan Sun, Third Military Medical University in Chongqing city, China.

(2) Farhana Tahseen Taj, KLE Academy of Higher Education, India.

(3) Katherine Gibson-Corley, University of Iowa, USA.

(4) Tan Kong Bing, NUHS, Singapore.

Complete Peer review History: <http://www.sciencedomain.org/review-history/24619>

Received 20th February 2018

Accepted 3rd May 2018

Published 16th May 2018

Case Report

ABSTRACT

Introduction: Cutaneous adnexal neoplasms have limitless morphologic varieties. Their clinical appearance is typically non-specific. To make a specific diagnosis of cutaneous adnexal neoplasm is important because some benign cutaneous adnexal tumours are markers of multiple endocrine neoplasms (MEN); others have a confirmed risk of transformation into malignant neoplasm. We noticed a paucity of data on the subject matter in our environment in particular and in Nigeria in general. This report is a case series of the histopathological types of cutaneous adnexal tumours over a 10 year period at the University of Benin Teaching Hospital (UBTH), Benin City, Edo state, Nigeria.

Methodology: It was a 10-year retrospective case series of cutaneous adnexal tumours seen in UBTH from January 2004-December 2013. Histology slides were retrieved, studied and lesions

*Corresponding author: E-mail: eradebamwen4real@yahoo.com;

characterized using the World Health Organization classification of cutaneous tumours. The data obtained from this study was analysed using the Statistical Package for Social Sciences, version 16 (SPSS 16, SPSSInc. Chicago, Illinois, United States of America).

Reports of Case Series: Cutaneous adnexal tumours (CATs) are rare in our own environment and accounted for 1.6% of all cutaneous (skin) tumours during the period under review. They occurred more commonly in males giving a male to female ratio of 5:1. There was neither a case of malignant CAT nor was there a case of cutaneous tumour of follicular or sebaceous differentiation reported. The benign cutaneous sweat gland tumours had a prevalence of 100% of the CATs. Eccrine poroma was the most common benign cutaneous sweat gland tumour and by extension the most common CATs.

Conclusion: Cutaneous adnexal tumours are relatively rare with their composition skewed in favour of the benign cutaneous tumours in general and benign cutaneous sweat gland tumours (eccrine and apocrine differentiation) in particular. Multicentre studies may help in giving a more acceptable conclusion for the Nigeria population.

Keywords: Case series; cutaneous adnexal tumours (CATs); benign cutaneous adnexal tumours; sweat gland tumours; eccrine poroma; hidradenoma.

1. INTRODUCTION

From the cutaneous (skin) appendages can arise an enormous number of adnexal neoplasms [1, 2]. These neoplasms have limitless morphologic varieties [1]. Previous studies done in Zaria, Nigeria [3] and Paraguay in South America [4] have shown a huge discordance between clinical diagnosis and histopathological diagnosis of cutaneous tumours. Nevertheless, histopathology remains the gold standard for the diagnosis of cutaneous diseases [5]. The clinical appearance of appendageal tumours is mostly non-specific. To make the specific diagnosis of cutaneous adnexal neoplasm is important [1]. The importance lies in the fact that while some benign cutaneous adnexal tumours (CATs) are markers of multiple endocrine neoplasms (MEN), others have a confirmed risk of transformation into malignant neoplasm [1]. Trichilemmomas and sebaceous adenomas are markers for MEN, [1] while very rarely porocarcinoma, hidradenocarcinoma and spiradenocarcinoma may arise from a pre-existent poroma, hidradenoma or spiradenoma respectively. In the same vein, although most BCC arises de novo, it can also in rare instances occur in pre-existent trichoblastoma (trichoepithelioma) [6]. We noticed a paucity of data on the subject matter in our environment in particular and in Nigeria in general. This report is a case series of the histopathological types of cutaneous adnexal tumours over a 10 year period at the University of Benin Teaching Hospital, Benin City, Edo state, Nigeria.

2. METHODOLOGY

This was a 10-year retrospective case series report that was carried out at the histopathology laboratory of the Department of Morbid Anatomy, University of Benin Teaching Hospital from 1st of January 2004 to December 31st, 2013. The targets of this study were all cases of cutaneous adnexal tumours (CATs) diagnosed histologically between January 2004 and December 2013. The surgical pathology register, histology request form and duplicate copies of the histology report were useful in providing information on the age, sex, nature of specimen, hospital number, histology laboratory number, clinical presentation and clinical diagnosis of each patient/case. Histology slides were retrieved, reviewed under the light microscope and the diagnosis recorded against the corresponding patient's name on a data spreadsheet. The World Health Organization classification of cutaneous appendageal tumours [6] was adopted for this study. The data obtained from this study was analysed using the Statistical Package for Social Sciences, version 16 (SPSS 16, SPSSInc. Chicago, Illinois, United States of America). The Ethical and Research committee of the teaching hospital gave due approval for this study after an application for the study was considered.

3. REPORTS OF CASE SERIES

The cutaneous adnexal tumours were 6 cases, Table 1. This represented 1.6% and 3.19% of all cutaneous tumours and benign cutaneous tumours respectively seen over the same period of this series of case reports. The mean age of those patients that developed cutaneous adnexal

tumours was 38.67 years (SD=26.30), while their median age was 32.50 years. Their age ranged from 14 to 83 years with a range of 69 years, Table 2. The patients with non-cutaneous adnexal tumours had a comparative mean age of 38.26 years, Table 2. As shown in Table 3, cutaneous adnexal tumours occurred more commonly in males giving a male to female ratio of 5:1.

Eccrine poroma and hidradenoma were the benign sweat gland derivative of adnexal cutaneous tumours seen in this study. Case one in the series of case reports of CATs was a fourteen (14) year old male who presented with an ulcerated growth of the left forearm for which no clinical impression was entertained. At cut up, a nodular lesion with an ulcerated centre that measures 3cm in length was noted. Histopathologic features were consistent with that of an eccrine poroma. Case two in the series was a 38 year old male with scalp swelling of 2 years duration. Swelling was in the occipital part of the scalp and it measured 5cm x5cm in two dimensions. There was an associated punctum discharging seropurulent effluent. A clinical diagnosis of infected sebaceous cyst was entertained. At cut up, the specimen was a skin tissue with a grey soft to firm mass below the skin covering and a nodular lesion elevated above its surface. While the whole specimen measures 5.2 cm x 3 cm x 2.4 cm, the nodular lesion measures 1.5 cm x 1.5 cm x 0.5 cm. Cut section reveals a cavity that span from the mass beneath the skin covering to the nodular lesion above this covering. This cavity contained light brown fluid with focal areas of gel like material. Histopathologic features were consistent with that of an eccrine poroma. The third case in the series of case reports was that of a 27 year old with new growth on the sole of right foot. The clinical impression by the managing Surgeon was query pyogenic granuloma (? pyogenic granuloma) and also query malignancy (? malignancy). He sent the specimen to the histopathologist for a more definitive diagnosis. Histopathologic features were consistent with that of an eccrine poroma. The fourth case in the series of case reports was that of a 16 year old male who presented with swelling of the left upper abdomen of 8 months duration. It had been progressively increasing in size. There was neither a history of preceding trauma nor associated pain. Examination revealed a soft mass on the left hypochondrium. It was not attached to the underlying structures but was attached to the overlying skin. Ultrasound

revealed a well-defined complex mass. There was no clinical diagnosis provided by the managing Surgeon. Specimen was sent to the Consultant of Consultants i.e. the Histopathologist for a definitive diagnosis. During cut up, specimen was a piece of yellow brown tissue with adherent dark skin that provided partial covering on one aspect. The specimen measured 6.5cmx2.9cmx2.5cm. Below the skin covering, was a circumscribed nodular mass that measured 1.8cm across. Cut section revealed a circumscribed lesion with multiple cystic cavities that were filled with brownish gelatinous material. Histopathologic features were consistent with that of an eccrine poroma. The 5th case in the series was an eighty three (83) year old male who presented with leg swelling. The clinical impression was that of a keratoacanthoma to rule out a malignant lesion. At cut up, the specimen was an ulcerated firm skin tissue that measured 3.5cmx2.5cmx1cm. The ulcer measured 1cmx1cm in two dimensions. Cut section showed yellow and white solid surface. Histopathologic features were consistent with that of a Hidradenoma. The 6th and last case in the series of reports of CATs was in a 54 year old female who presented with skin swelling. The site was noted to be on the lower limb as specified in Table 4. There was no clinical diagnosis for this case. Skin biopsy done was sent to the Pathologist and it turned out to be a Hidradenoma.

Eccrine poroma accounted for 66.67% of adnexal tumours while hidradenoma accounted for 33.33% of cases of adnexal tumours, Table 3. Eccrine poroma accounted for 4 cases of adnexal tumours which represented 1.1% and 2.13 % of all cutaneous tumours and benign cutaneous tumours respectively, thus making it the 13th and 8th most common tumour of the former and later respectively during the study period. These 4 cases occurred solely in males giving a male to female ratio of 4:0. The mean age for the development of eccrine poroma was 23.75 years (SD = 11.09) with an age range of 14 – 38 years and a peak in the 2nd decade, Table 3. This also serves as the peak incidence in males. The head and neck, the trunk, the upper limb and lower limb were sites for eccrine poroma, Table 4. Histologic sections of eccrine poroma show a benign neoplastic lesion composed of broad intraepidermal anastomosing bands of epithelial cells enclosing cystic spaces. The cells are uniformly cuboidal with a round deeply basophilic nucleus. The peripheral cells show no palisading. Ductal lumen lined by eosinophilic cuticle is present within the band of

cells. The stroma is highly vascularised. See Fig. 1. Hidradenoma accounted for 2 cases which represented 0.5% and 1.06% of all cutaneous tumours and benign cutaneous tumours respectively. It was the least most common cutaneous and benign cutaneous tumour observed during the period under review. Of the 2 cases, 1 case each occurred in males and females giving a male to female ratio of 1:1. The mean age for Hidradenoma was 68.50 years (SD = 20.51) with an age range of 54–83 years,

Table 3. The trunk and lower limb were sites for this tumour in this study, Table 4. Histologic sections of hidradenoma show an unencapsulated benign neoplastic multilobular dermal lesion that is composed of closely arranged tumour cells whose shape ranges from polygonal to fusiform to round. Their cytoplasm is either clear or eosinophilic. The nuclei in the cells of the former are smaller than that in the latter. The stroma is fibrous tissue with areas of hyalinised collagen. See Fig. 2.

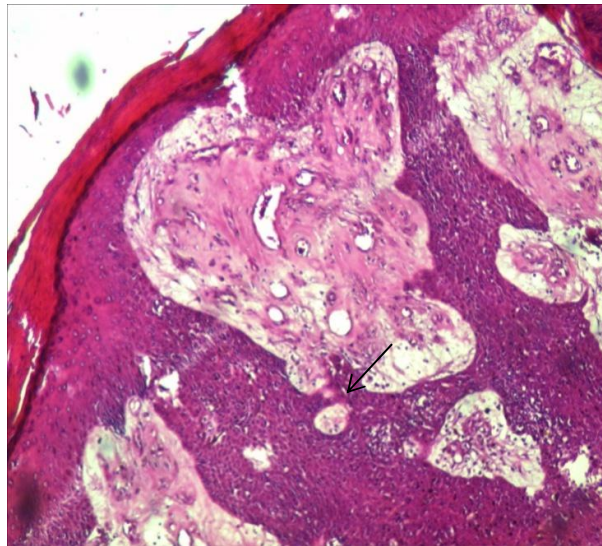


Fig. 1. Histologic section of an eccrine poroma shows an abrupt delineated intraepidermal sheet-like down-growth of proliferating monomorphous dark cuboidal cells. The stroma is vascularized and a ductal structure is present (arrow). H and E, x 100 magnification

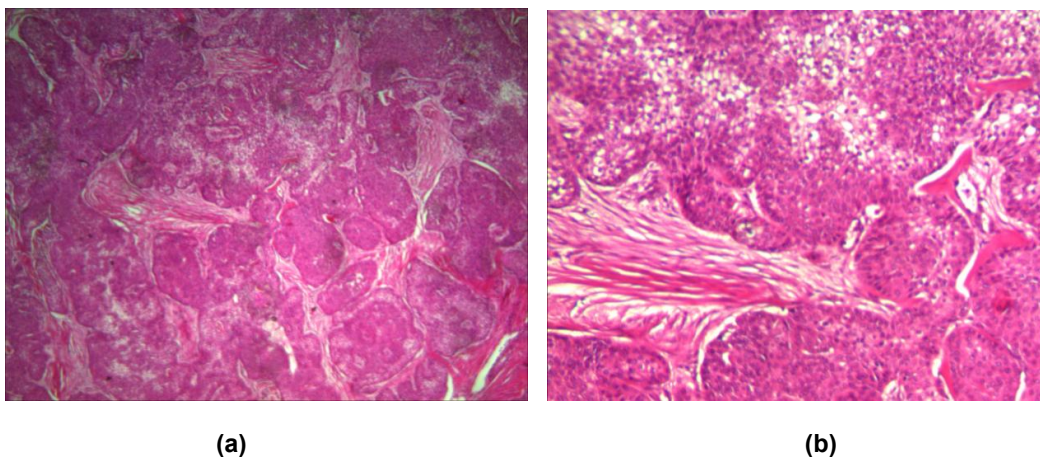


Fig. 2. Histologic sections of a hidradenoma show a multilobular dermal tumour containing polyhedral, fusiform and clear cells. The latter (clear cells) has clear cytoplasm while former (polyhedral and fusiform) have eosinophilic cytoplasm. The stroma between the lobules varies from focal areas of hyalinized collagen to fibrous tissue. H and E, (a); x40 magnification, (b) x 100 magnification

Table 1. Benign and malignant distribution of cutaneous tumours

Lesion	Frequency		Total
	Benign	Malignant	
Cutaneous adnexal tumour	6	0	6
N	182	187	369
Total	188	187	375

N = Cutaneous tumours excluding the adnexal group

Table 2. The age (mean, minimum, maximum and range) and, percentage distributions of cutaneous adnexal and non-adnexal tumours

Cutaneous tumours	Age				Percentage (%)
	Mean age \pm SD	Minimum	Maximum	Range	
Adnexal	38.26 \pm 26.30	14	83	69	1.6
N	38.26 \pm 19.34	1	111	110	98.4

N = Cutaneous tumours excluding the adnexal group

4. DISCUSSION

This report of the case series of cutaneous adnexal tumours (CATs) showed that they were relatively rare and were solely made up of benign tumours. These findings are consistent with findings of previous studies which have shown that cutaneous adnexal tumours are rare, [7,8] and are predominantly benign, [3,4,9-11] with the benign tumours accounting for 80.36 - 100% of all CATs in the world literature [4,7,8,11]. Samaila [3] (Zaira), Janota [12] (Ibadan) and Solomon et al. [13] (Kano) documented comparative figures of 86 – 90% of benign CATs in Nigeria. Benign sweat gland tumours are by far the most common cutaneous adnexal tumours. Studies done by Gonzalez et al. [4] (Asuncion, Paraguay), Nair [14] (Kerala, India), Jindal and Patel [7] (Baroda, India) and Sharma et al. [11] have shown that benign sweat gland tumours account for 42.86 - 57.56% of all CATs. In Nigeria, Solomon et al [13] (Kano) reported a comparative similar figure of 50%, unlike Samaila [3] (Zaira) and Janota [12] (Ibadan) that documented higher figures of 67.3 and 70% respectively. This series of case reports seems to be in agreement with most previous studies, [3,4,7,10-14] in that benign sweat gland tumours are by far the most common of all the adnexal tumours of the skin, it however has a much higher prevalence (100%) in comparison to these studies. Eccrine poroma followed by hidradenoma were the most common benign CATs in this report of case series, unlike the study from Kano, Nigeria by Solomon et al. [13] that reported that hidradenoma followed by eccrine poroma were the most common benign CATs. The benign tumours of follicular differentiation are the second most common of all

the CATs. Previous studies [4,7,11,14] from Asuncion (Paraguay), Kerala, Kolhapur/Maharashtra and Baroda (India) have shown that it accounted for 36.36 – 44% of all the skin adnexal tumours. Samaila [3] (Zaira), Janota [12] (Ibadan) and Solomon et al [13] (Kano) reported that of all skin adnexal tumours, the benign tumours of follicular differentiation accounted for 7.7%, 20% and 29.3% respectively. Jayalaksmi and Looi [15] (Malaysia) reported that CATs of follicular differentiation (hair follicle origin) were the most common cutaneous adnexal tumours seen in their study where it accounted for 63.4% of cases, unlike the aforementioned previous studies where sweat gland tumours predominate. Unlike these studies, [3,4] this report of case series fell short of reporting a case of benign tumour of follicular differentiation. Several studies have reported that benign tumours of sebaceous differentiation are the least common of all skin adnexal tumours, [3,4,7,8,12,14] while this report of case series did not report a case of this sub group of benign CATs. Kamyab-Hesari et al. [16] (Iran) however reported that CATs of sebaceous differentiation were the most common cutaneous adnexal tumour observed in their study and it accounted for 536 cases (52.7%) of the 1016 cases of cutaneous adnexal tumour. Four hundred thirteen (413) cases of the 536 cases of CATs of sebaceous differentiation were Nevus Sebaceous of Jadassohn. The World Health Organization classification of cutaneous appendageal tumours [6] that was adopted for this study excluded Nevus Sebaceous of Jadassohn as a primary cutaneous neoplasm. This lesion is a hamartoma that is often found on the scalp at birth, [17] and it has propped tumours of sebaceous differentiation as the most common CATs.

Table 3. Frequency, age and sex distribution of adnexal tumours

Adnexal tumours	Frequency			Male: Female	Mean \pm SD (years)	Age range (year)	Peak age	Mean age (years) \pm SD		Peak age (years)	
	No of cases (%)	Male (no.)	Female (no.)					Male	Female	Male	Female
Benign											
EP	4 _(66.67)	4	-	4:0	23.75 \pm 11.09	14 – 38	10 – 19	23.75 \pm 11.09	-	10-19	-
HID	2 _(33.33)	1	1	1:1	68.50 \pm 20.51	54 – 83	-	-	-	-	-
Total	6 ₍₁₀₀₎	5	1	5:1							

Table 4. Site distribution of adnexal tumour

Skin tumour	Head/Neck	Anogenital	Trunk	Lower limb	Upper limb	No. of cases with specified site
Benign adnexal tumours						
ECPO	1	0	1	1	1	4
HID	0	0	1	1	0	2
Total	1	0	2	2	1	6

Key: ECPO =Eccrine Poroma; HID = Hidradenoma

The World Health Organization (WHO) documented that benign neoplasms occur predominantly in younger patients when compared to the malignant tumours [6]. In this report of case series, eccrine poroma align with this documented observation as it was seen in the 2nd to the 4th decade unlike nodular hidradenoma that was seen in the middle age and elderly. Overall, the finding of this report of case series is in agreement with WHO documentation, in that the majority of the study population (66.67%) were seen in younger patients, more so that the mean age of development of CATs which also doubles for that of benign CATs in this report of case series was 38.67 years, i.e within the young age group. The mean age (37 years) for the development of CATs in Kano, [13] Nigeria is comparatively similar to that of this report of case series. Previously, studies have shown that malignant CATs of sweat gland origin are more common than those of follicular or sebaceous differentiation [3,4,7,8,12,14] Studies done in Zaira, [3] Ibadan [12] and Kano [13] have reported that malignant sweat gland tumours accounted for 10% , 11.5% and 14% of all skin adnexal tumours respectively. The predominant histological variant of the sweat and pilosebaceous gland tumours varies between studies [3,4,7,8,14] Contrary to these studies, there was no observable case of malignant adnexal tumour in this report of case series. This observation is not surprising bearing in mind that CATs have earlier been noted as relatively rare tumours that are mainly benign and had been reported to have accounted for up to a 100% of cutaneous adnexal tumours. This report of case series reported a male preponderance unlike Solomon et al. [13] that observed no sexual predilection and several other previous studies that have documented a female preponderance [3,4,7,8,14]. The cause of cutaneous adnexal neoplasm is unknown in the majority of cases, however autosomal dominant mutation in a tumour suppressor gene has been implicated in some [6]. Benign CATs present clinically as smooth surfaced, symmetrical papules or nodules that have the same colour as the patient's skin or darker [6]. Some adnexal neoplasm, such as sebaceous adenoma and syringocystadenoma papilliferum, have eroded surfaces, but in general, ulceration is a sign of malignancy [6]. The ulcerated lesions in this report of case series turned out to be benign. Most cutaneous adnexal carcinomas are irregularly shaped plaques, sometimes ulcerated [6].

5. CONCLUSION

In conclusion, the findings of this report of case series seems to have reinforced that of previous studies in that CATs are relatively rare with their composition skewed in favour of the benign CATs in general and benign sweat gland tumours in particular. Perhaps, future studies should be multi-institutional. This may lead to an increase in the numbers of CATs. A more acceptable conclusion than the findings of this case series for the Nigeria population may be derived from data generated from these various health institutions. This is without prejudice that some benign cutaneous adnexal tumours are markers of multiple endocrine neoplasms (MEN) while others have a confirmed risk of transformation into malignant neoplasm.

CONSENT

It is not applicable.

ETHICAL APPROVAL

As per international standard or university standard, written approval of Ethics committee has been collected and preserved by the authors.

COMPETING INTERESTS

Authors have declared that no competing interests exist.

REFERENCES

1. Santa Cruz DJ, Hurt MA. Nonmelanocytic cutaneous tumors. In: Mills S.E, editor. Sternberg's Diagnostic Surgical Pathology, 4th edition. Philadelphia: Lippincott Williams and Wilkins. 2004;49-88.
2. Wick MB, Glembocki GJ, Teague MW, Patterson JW. Cutaneous tumors and tumor-like conditions. In: Silverberg SG, editors. Silverberg's Principle and Practice of Surgical Pathology and Cytopathology, 4th edition. Philadelphia : Churchill livingstone Elsevier. 2006;241-306.
3. Samaila MOA. Adnexal skin tumours in Zaria, Nigeria. Ann Afri Med. 2008;7(1): 6-8.
Available:<http://www.annalsafmed.org/text.asp?2008/7/1/6/55691>
(Last viewed on October 10, 2013)

4. Gonzalez L, Di Martino B, Rodriguez M, Knopfmacher O, Bolla L, Recalde J. Clinical and epidemiological study of adnexal tumours at the Dermatology Department of the Medical Sciences Faculty, National University of Asuncion. Paraguay, 2002-2008. *Folia Dermatol.* 2009;20(3):135-139.
5. Werner B. Skin biopsy and its histopathologic analysis: Why? What for? How? Part I. *An Bras Dermatol.* 2009; 84(4):391-395.
6. LeBoit PE, Burg G, Weedon D, Sarasain A. (eds.): World Health Organization Classification of Tumours. Pathology and Genetics of Skin Tumours. Lyon: IARC Press; 2006.
7. Jindal U, Patel R. Study of adnexal tumors of the skin: A three year study of 25 cases. *The Internet Journal of Pathology.* 2012; 13:(13). Available:<http://ispub.com/IJPA/13/3/14236> (Last viewed on April 14, 2014)
8. Saha A, Das NK, Gharami RC, Chowdhury SN, Datta PK. A clinico-histopathological study of appendageal skin tumors, affecting head and neck region in patients attending the dermatology opd of a tertiary care centre in Eastern India. *Indian J Dermatol.* 2011;56(1):33-36.
9. Mohan H. Text book of pathology, 6th edition. Ltd, New Delhi: Jaypee Brothers Medical Publishers (P); 2010.
10. Radhika K, Phaneendra BV, Rukmangadh N, Reddy MK. A study of confirmed skin adnexal tumours: Experience at a tertiary care teaching hospital. *J Clin Res.* 2013;2: 132-8.
11. Sharma A, Paricharak DG, Nigam JS, Rewri S, Soni PB, Omhare A, et al. Histopathological study of skin adnexal tumours- Institutional study in South India. *J Skin Cancer;* 2014. Available:<http://dx.doi.org/10.1155/2014/543756> (Last viewed March 8, 2018)
12. Janota I. Adnexal skin tumours in Nigeria. *Brit J Dermatol.* 1967;79(5):259-266.
13. Solomon R, Yusuf I, Ochicha O. Skin adnexal tumours in Kano, Northern Nigeria. *Niger J Basic Clin Sci.* 2015;12: 51-4.
14. Nair PS. A clinicopathologic study of skin appendageal tumors. *Indian J Dermatol Venereol Lepro.* 2008;74:550-553.
15. Jayalaksmi P, Looi LM. Cutaneous adnexal neoplasms in biopsy specimens processed in the Department of Pathology, University of Malaysia. *Ann Acad Med Singapore.* 1996;25:522-5.
16. Kamyab-Hesari K, Balighi K, Afshar N, Aghazadeh N, Rahbar Z, Seraj M, et al. Clinicopathological study of 1016 consecutive adnexal skin tumours. *Acta Med Iran.* 2013;51:879-85.
17. Segars K, Gopman JM, Elston JB, Harrington MA. Nevus Sebaceus of Jadassohn. *Eplasty.* Available:<https://www.ncbi.nlm.nih.gov/pmc/articles/PMC4518814/> (Last viewed on March 04, 2018)

© 2018 Dele and Akhator; This is an Open Access article distributed under the terms of the Creative Commons Attribution License (<http://creativecommons.org/licenses/by/4.0>), which permits unrestricted use, distribution, and reproduction in any medium, provided the original work is properly cited.

Peer-review history:

The peer review history for this paper can be accessed here:
<http://www.sciencedomain.org/review-history/24619>