



Metabolic Ketoacidosis in a Gravida Diagnosed with COVID-19: A Case Report

**Sparsh Madaan¹, Dhruv Talwar², Sunil Kumar², Arpita Jaiswal^{1*},
Neema Acharya¹, Sourya Acharya² and Dhruva Halani¹**

¹Department of Obstetrics and Gynaecology, Jawaharlal Nehru Medical College, Datta Meghe Institute of Medical Sciences (Deemed to be University), Wardha, Maharashtra, India.

²Department of Medicine, Jawaharlal Nehru Medical College, Datta Meghe Institute of Medical Sciences (Deemed to be University), Wardha, Maharashtra, India.

Authors' contributions

This work was carried out in collaboration among all authors. All authors read and approved the final manuscript.

Article Information

DOI: 10.9734/JPRI/2021/v33i45A32750

Editor(s):

(1) Dr. Q. Ping Dou, Wayne State University, USA.

(2) Dr. R. Deveswaran, M.S. Ramaiah University of Applied Sciences, India.

(3) Dr. Alyautdin Renad N, Scientific Centre for Expert Evaluation of Medicinal Products, Russia.

Reviewers:

(1) C. Mohan Rao, KIIT University, India.

(2) Subodh Kumar Mahto, Atal Bihari Vajpayee Institute of Medical Sciences (ABVIMS) and Dr. Ram Manohar Lohia Hospital, India.

(3) Marcus Fernando da Silva Praxedes, Centro Ciências da Saúde, Universidade Federal do Recôncavo da Bahia, Brazil.

(4) Fei Yee Lee, Malaysia.

(5) Yoshito Tsushima, Gunma University Graduate School of Medicine, Japan.

Complete Peer review History: <https://www.sdiarticle4.com/review-history/73123>

Case Report

Received 14 August 2021

Accepted 27 September 2021

Published 01 October 2021

ABSTRACT

We present a case of term pregnancy which presented with chief complaint of Breathlessness, chest pain as well as a one day history of vomiting. She tested positive for COVID19 through reverse transcriptase polymerase chain reaction of nasopharyngeal swab and the symptoms were attributed to Pneumonia caused due to COVID19. However, the arterial blood gas showed metabolic acidosis with high anion gap. This was a non lactate acidosis with no hypoxemia. Most reasonably the state of pregnancy with increased energy demands along with increased metabolic maternal demand due to infection coupled with maternal starvation had resulted in this Ketoacidosis. In view of non progression of labor caesarian section was carried out and a healthy neonate was delivered. There was an initial improvement in maternal ketoacidosis post partum however optimal management of COVID19 pneumonia required oxygen support and use of corticosteroids. Thus we highlight how an unusual metabolic demands of pregnancy might mimic COVID 19.

*Corresponding author: E-mail: drarpitajaiswal@gmail.com;

Keywords: COVID19; metabolic acidosis; severe acute respiratory syndrome.

1. INTRODUCTION

The virus known as Severe Acute Respiratory Syndrome Coronavirus 2 (SARS CoV 2) and its associated disease COVID19 has brought up challenging times for clinicians throughout the world. It was initially the unfamiliarity with the course of COVID19 and then the unusual presentations associated with it that made it difficult to predict the presentation and outcome of COVID19. Clinicians throughout the world have been working tirelessly to fight this pandemic on the frontline and new repurpose drugs like remdesivir are offering hope of better outcome in covid with pregnancy. The morbidity, mortality pattern in India has shown increasing trend in some states, and predominant involvement of the respiratory tract has been found.

It is now well established that the clinical manifestations of COVID19 may range from a completely asymptomatic patient to severe respiratory distress with ICU care requiring ventilatory support [1]. Despite the increase in knowledge about COVID19 there has been some lacunae in the knowledge about its effect in pregnancy. There have been unique presentations of COVID19 in pregnancy including a overlap with HELLP Syndrome.

Here we report a rare case of Metabolic Acidosis as the presenting feature in COVID19 infected female who was non diabetic.

2. CASE REPORT

A 24 year old primigravida with the gestational age of 38 weeks presented in the emergency department with high grade fever, headache, fatigue, vomiting and nausea. There was no history of diabetes mellitus, hypertension, bronchial asthma or thyroid disorder in the past. Her pregnancy was uneventful and gestational diabetes had been ruled out. Obstetric history revealed duration of marriage to be 15 months and two doses of tetanus toxoid was received. Menstrual history revealed last menstrual period to be 40 weeks prior to her presentation. Patient had no history of COVID19 vaccination.

On general examination patient was febrile with temperature of 101 degree Fahrenheit, pulse was 112 beats per minute regular in rhythm, blood pressure was 124/76 mm hg in sitting

position spo2 was 98 percent on room air and respiratory rate was 32 per minute.

On systemic examination Uterus was term in size, relaxed, cephalic, fetal heart sounds were heard and were normal, 144 beats per minute. On per vaginal examination os was 2 cm dilated, 25 percent effaced and station was -2, membranes present, presenting part vertex, show present, pelvis seemed to be adequate. Oxytocin 2.5 units was given and titration of oxytocin was done and in view of non-progression of labor, emergency caesarian section was done. A healthy neonate weighing 2.98kgs was born with APGAR score of 8/10 at one minute and 9/10 at five minutes. A nasopharyngeal Swab for COVID19 was sent for the patient and it came out to be positive through reverse transcriptase polymerase chain reaction method. Patient was admitted for further work up and lab investigations were sent (Table 1). Urinary tract infection was ruled out. A broad differential diagnosis was prepared ranging from pulmonary causes to cardiac, gastroenterological and obstetric causes. Pre Eclampsia was ruled out first due to the absence of hypertension, no hemolysis observed in the lab investigations, liver enzymes were within normal limits and platelet count were also in normal limit. There was no proteinuria as well. ECG was done which ruled out ischemia and arrhythmia. D-dimer was 2.12 mcg/ml, hence a 2D echo was carried out which was normal ruling out pulmonary embolism. An CT Thorax was done which showed CT Severity Score of 5 and CORAD 6. Urine and Blood Culture were also negative. Sputum culture was also done and came out to be negative.

Arterial Blood Gas showed metabolic acidosis along with compensation done by the respiratory component. Renal function test and liver function test were also normal.

Urine routine testing was positive for ketone bodies. Supportive management in the form of intravenous fluids was done to treat the metabolic acidosis. Potassium and bicarbonate supplementation was given along with 5% Dextrose to prevent formation of more ketone bodies. Patient was treated throughout hospital stay with rigorous fluid therapy in the form of normal saline and dextrose. Low molecular weight heparin was started along with remdesivir, steroids and other supportive measures.

Paracetamol was withdrawn from the treatment protocol to prevent oxoproline formation [2]. Arterial Blood gas showed improvement and throughout hospital stay patient's oxygen saturation remained from 96 to 99 percent on room air. She was given oxygen support of 2 litre on admission which was stopped on day five of admission. Patient was ultimately discharged 5 days after admission in stable condition.

3. DISCUSSION

We report a pregnant female with COVID19 manifesting as Metabolic Acidosis which was not associated with diabetes. Our patient was having gastrointestinal manifestations like nausea and vomiting attributed to COVID19 which led to decrease in food intake. Starvation might have precipitated the ketoacidosis. This was synergized by the increased metabolic demand during pregnancy. It is also another example of

illustration of COVID19 manifestation ranging outside the usual pulmonary system. Arterial Blood Gas analysis of our patient showed metabolic acidosis with high anion gap. The reason for this high anion gap was not lactate or any toxic agent ingestion. Urine analysis further showed ketone bodies. A normal Hba1c and fasting blood sugar levels along with history of prior checkup for gestational diabetes ruled out diabetic cause for this ketoacidosis. Remaining diagnosis remained of Starvation Ketoacidosis attributing to increased nausea and vomiting in her history and due to increased metabolic demand seen in pregnancy [3]. Starvation ketoacidosis is seen in non-diabetic patients with prolonged starving. A pregnant female produced comparatively more ketone bodies than a non pregnant patient. Thus there is increased risk of metabolic acidosis owing to the starvation and increased metabolic rate in pregnancy.

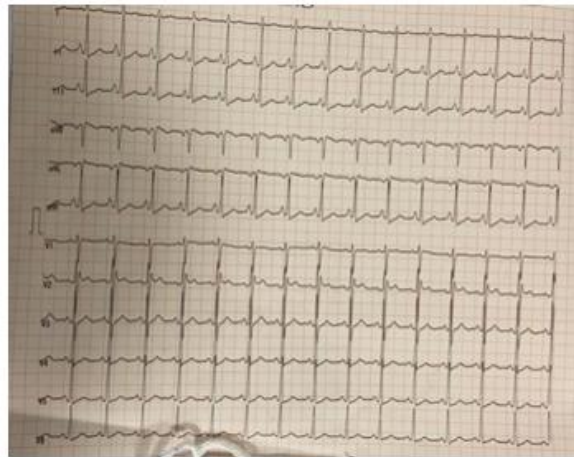


Fig. 1. ECG showing Sinus Tachycardia

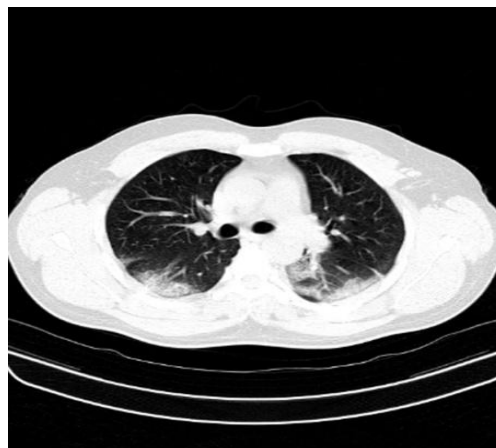

Fig. 2. CT Thorax showing mild bilateral lower lobe Ground glass opacity

Table 1. Showing lab investigations of the case

CBC	Hb-12.5 gm/dl(normal-13.5 to 17.5 grams per decilitre) MCV-89fl(normal range-80 to 100fl) Platelet count-120000/microlitre(normal range 150000 to 400000/microlitre),WBC Count -7900/microlitre(normal – 4500 to 11000/microlitre)
LFT	Neutrophil-85%,lymphocyte-14%,eosinophil-1%,N:L Ratio-6.07 Total Protein-6.8gm/dl(normal- 6.0 to 8.3 grams per deciliter (g/dL), Albumin3.4gm/dl(normal-3.4 to 5.4 g/dL) Globulin3.4gm/dl(Normal-.0 to 3.5 g/dL), aspartate aminotransferase 29 units/l (Normal- 8 to 33 U/L), alanine aminotransferase 21units/l(Normal- 4 to 36 U/L), Alkaline phophatase 97IU/l(Normal 20 to 140 IU/L), Total Bilirubin :1.35mg/dl(normal- <1.2mg/dL)
KFT	Creatinine:0.9mg/dl(Normal- 0.59 to 1.04 mg/dL), Urea33mg/dl(Normal- 5 to 20 mg/dl), Sodium134mmol/l(135 to 145 mEq/L),Potassium -4.4mmol/l(3.5 mmol/L to 5.1 mmol/L)
CRP	49.0mg/dl(Normal- below 3.0 mg/L)
D-Dimer	2.12cg/ml (Normal- < 0.4 mcg/mL)
Serum Ferritin	640ng/ml(Normal- 10 to 120 ng/mL)
Urine	Positive for Ketone.0 mmol/L (Normal range-0.6 to 1.5 mmol/L)
Arterial Blood Gas	pH 7.33 (Normal-7.35-7.45) pCO2 2.0 kpa(Normal- 4.4–6.3 kPa) Bicarbonate 9.1 mmol/l(Normal- 23–29 mmol/L) Base excess -13.3 mmol/l(Normal- –3 to 3 mmol/L) pO2 18.8 kpa(Normal- 10–13.3 kPa) O2 haemoglobin 98.4%(Normal- 95%–100%) Anion Gap 25(Normal 12+ or – 2)
HbA1c	5.35% (normal 4-5.6%)
Fasting Blood Sugar	88mg/dl(Normal <100mg/dl)

Insulin Resistance and reduced secretion of insulin is observed in pregnancy leading to increased ketone body formation. Insulin is antagonized by hormones produced by the placenta thus leading to increased insulin resistance. In a state of stress, the secretion of these hormones increases leading to increased breakdown of lipids forming free fatty acids. These free fatty acids leads to formation of ketone bodies which might be detected in urine. Furthermore, the ability of a person to compensate acidosis is compromised in pregnancy as there is increase in minute ventilation of the alveoli causing alkalosis of respiratory type. However, kidney compensates for the same by increased excretion of bicarbonate. This leads to a decrease in the buffering capacity of bicarbonate which is most evident in the final term of pregnancy[4].

COVID19 itself also promotes acidosis, by promoting a state of insulopenia. Also, Interleukin 6 plays a role in ketoacidosis by causing a

maladaptive immune response to severe acute respiratory syndrome coronavirus 2. Thus, Interleukin 6 might act as a driver for ketosis (Li et al., 2020). Another postulate is COVID19 induced lipolysis leads to fatty acid formation and ultimately ketoacidosis. It is important to note that our patient did not have a very severe COVID19 pneumonia, she had bilateral lower lobe infiltration which was minimal but characteristic of COVID19 pneumonia [5].

The decision to terminate the pregnancy was made in view of non-progression of labor. Also, at term with growth of the foetus, residual volume of lungs decrease. This might lead to precipitation of hypoxia.

Thus COVID19 pregnancy at term should be managed judiciously.

The biggest threat in our case was not from hypoxia but metabolic acidosis. If the mother suffers from acidosis there is resultant decrease

in uterine blood flow causing fetal hypoxia [6]. Acidosis In the mother will also increase the affinity of maternal hemoglobin to oxygen which will lead to decreased supply of oxygen to the fetus [7]. Maternal acidosis also leads to breakage of ketoacids to hydrogen ions and organic which might cross the placenta leading to fetal acidosis [8]. Thus, trial for labor might increase the metabolic demand of patient further increasing acidosis.

There have been previous reports of COVID 19 associated with HELLP syndrome, severe cytokine storm and severe respiratory failure in pregnancy, however COVID19 presenting as metabolic ketoacidosis in pregnancy remains a rare and underreported presentation of COVID19 [9,10,11]. Through this brief case report we have tried to highlight the challenges of managing metabolic acidosis complicated by COVID19 in a pregnant female and the importance of recognizing COVID19 as a culprit behind metabolic abnormalities witnessed in a pregnancy.

4. CONCLUSION

Hence, we conclude that ketoacidosis witnessed in pregnancy might not always be a sign of underlying diabetes. There is growing evidence to support the role of COVID19 behind metabolic ketoacidosis. Also, augmentation or trial for a normal labour might increase metabolic demand further exacerbating acidosis, hence optimal medical management of a Pregnant Female with COVID 19 induced metabolic acidosis requires a vigilant mind and prompt management to prevent maternal and fetal mortality.

DISCLAIMER

The products used for this research are commonly and predominantly use products in our area of research and country. There is absolutely no conflict of interest between the authors and producers of the products because we do not intend to use these products as an avenue for any litigation but for the advancement of knowledge. Also, the research was not funded by the producing company rather it was funded by personal efforts of the authors.

CONSENT AND ETHICAL APPROVAL

As per university standard guideline, participant consent and ethical approval have been collected and preserved by the authors.

COMPETING INTERESTS

Authors have declared that no competing interests exist.

REFERENCES

1. Prokop M, van Everdingen W, van Rees Vellinga T, et al. CO-RADS: a categorical CT assessment scheme for patients suspected of having COVID-19-Definition and evaluation. *Radiology*. 2020;296:E97–104.
2. Emmett M. Acetaminophen toxicity and 5-oxoproline (pyroglutamic acid): a tale of two cycles, one an ATP-depleting futile cycle and the other a useful cycle. *Clin J Am Soc Nephrol*. 2014;9(1):191-200.
3. Lain KY, Catalano PM. Metabolic changes in pregnancy. *Clin Obstet Gynecol*. 2007; 50(4):938-48.
4. Liss DB, Paden MS, Schwarz ES, et al. What is the clinical significance of 5-oxoproline (pyroglutamic acid) in high anion gap metabolic acidosis following paracetamol (acetaminophen) exposure? *Clin Toxicol*. 2013;51:817–27
5. Jain A, Talwar D, Kumar S. Spectrum of Respiratory Involvement in COVID 19 Era; An Overview. *Indian Journal of Forensic Medicine & Toxicology*. 2020;14(4): 6593-9.
6. Li T, Lu H, Zhang W. Clinical observation and management of COVID-19 patients. *Emerg Microbes Infect*. 2020;9:687–90.
7. Carroll MA, Yeomans ER. Diabetic ketoacidosis in pregnancy. *Crit Care Med* 2005;33:S347–53.
8. Bobrow CS, Soothill PW. Causes and consequences of fetal acidosis *Archives of Disease in Childhood - Fetal and Neonatal Edition*. 1999;80:F246-F249.
9. Mahajan O, Talwar D, Kumar S, Jaiswal A, Madaan S, Khanna S, Shah D. Fatal HELLP syndrome in pregnancy: A sequelae of Long COVID?. *Medical Science*. 2021;25(114):1878-1881.
10. Halani D, Jaiswal A, Kumar S, Talwar D, Madaan S. Post natal COVID-19 induced severe acute respiratory distress syndrome managed with monoclonal antibody and prone ventilation. *Medical Science*. 2021; 25(112):1427-1431.

11. Madaan S, Jaiswal A, Kumar S, Dewani D, Talwar D, Khanna S. Cytokine storm treated successfully with immunoglobulin therapy in a pregnant COVID-19 patient. *Medical Science*, 2021;25(112):1413-1416.

© 2021 Madaan et al.; This is an Open Access article distributed under the terms of the Creative Commons Attribution License (<http://creativecommons.org/licenses/by/4.0>), which permits unrestricted use, distribution, and reproduction in any medium, provided the original work is properly cited.

Peer-review history:

The peer review history for this paper can be accessed here:

<https://www.sdiarticle4.com/review-history/73123>