



Pelvic Desmoid Tumour Imitating Uterine Leiomyoma in a Nigerian Premenopausal Woman

**Mustapha Akanji Ajani^{1*}, Taamaka Davis Ngubor²,
Nkadinma Florence Nkwogu³, John Sotunsa⁴ and Adebola Yusuf⁵**

¹*Department of Pathology, College of Medicine, University of Ibadan and University College Hospital, Ibadan, Oyo State, Nigeria.*

²*Department of Internal Medicine, Babcock University Teaching Hospital, Ilishan-Remo, Ogun State, Nigeria.*

³*Department of Haematology, Babcock University Teaching Hospital, Ilishan-Remo, Ogun State, Nigeria.*

⁴*Department of Obstetrics and Gynecology, Babcock University Teaching Hospital, Ilishan-Remo, Ogun State, Nigeria.*

⁵*Department of Radiology, Babcock University Teaching Hospital, Ilishan-Remo, Ogun State, Nigeria.*

Authors' contributions

This work was carried out in collaboration among all authors. Author MAA designed the study, managed the literature searches, performed the histopathology, wrote the histopathology report and description. Authors TDN and NFN wrote the first draft of the manuscript and managed the literature searches. Author JS did the surgery and managed the literature searches. Author AY managed the literature searches and wrote the Computed Tomography scan report. All authors read and approved the final manuscript.

Article Information

DOI: 10.9734/JAMMR/2020/v32i230372

Editor(s):

(1) Dr. Ione Maria R. Soares Lopes, Federal University of Piaui (UFPI), Brazil.

Reviewers:

(1) Adeniyi Stephen Afolabi, Federal Medical Centre, Nigeria.

(2) Qi Cheng, China.

(3) Arthur N. Chuemere, University of Port Harcourt, Nigeria.

Complete Peer review History: <http://www.sdiarticle4.com/review-history/54612>

Case Report

Received 03 December 2019

Accepted 10 February 2020

Published 04 March 2020

ABSTRACT

Aim: To describe a rare case of pelvic desmoid tumour simulating as a huge uterine leiomyoma causing a diagnostic dilemma in a premenopausal woman.

Case Presentation: This was a 44-year-old, para 2 (2 alive) who was referred to our gynaecology clinic from a secondary health facility on account of slowly increasing abdominal swelling of 2 years

*Corresponding author: E-mail: ajanimustapha42@gmail.com;

duration. There was no nausea, vomiting or diarrhoea. There was associated mild to moderate dull lower abdominal pain that did not radiate to any other part of the body. There was no change in her monthly menstrual flow. Physical examination revealed a pelvic mass about 32 weeks pregnancy size and firm. Computed Topography scan showed a huge pedunculated sub-serous uterine fibroid. A huge mass adherent to the anterior surface of the body of the uterus was completely surgically excised at exploratory laparotomy. Histology of the excised tumour revealed a definitive histological diagnosis of pelvic desmoid tumour. The patient was clinically stable and discharged home 10 days post operation and was followed-up on out-patient gynaecology clinic basis.

Discussion: Pelvic desmoid is a rare mesenchymal tumour caused by abnormal proliferation of fibroblasts. It is three times more common in women and occurs mostly between 25 and 35 years of age which correspond to the same age peak incidence for uterine fibroids. The tumour can easily be misdiagnosed as uterine leiomyoma and imaging cannot reliably distinguish the two conditions.

Conclusion: Pelvic desmoid tumour should be considered as a differential diagnosis in premenopausal women who present with abdominal swelling. Relevant clinical history, Radiological imaging and Histopathological assessment are essential in making prompt accurate diagnosis.

Keywords: Pelvic desmoid tumour; uterine leiomyoma; Babcock University; Nigeria.

1. INTRODUCTION

Desmoid tumours are mesenchymal tumours which arise from excessive proliferation of fibroblasts [1]. They are relatively rare and account for about 0.03% of all soft tissue tumours [2]. Even though they exhibit benign morphology they are still classified as intermediate malignant neoplasm due to their great propensity to infiltrate adjacent structures and their high rate of local recurrence even after radical excision [3,4]. Desmoid tumours can be classified into extra-abdominal, abdominal wall and intra-abdominal; intra-abdominal being the least common [5]. The aetiology is not known but it has been associated with trauma including previous surgeries, estrogenic hormonal abnormalities and a family history of polyposis coli [4,6]. This is probably why it is 3 times more common in women than in men and occurs mostly between 25 and 35 years [4,6,7]. These tumours cannot be distinguished from other soft tissue tumours by imaging [1]. We report a sporadic case in a 44-year-old premenopausal Nigerian woman.

2. CASE REPORT

This was a 44-year-old, para 2 (2 alive) who was referred to our gynaecology clinic from a secondary health facility on account of slowly increasing abdominal swelling of 2 years duration. There was associated mild to moderate dull lower abdominal pain that did not radiate to any other part of the body. There was no nausea, vomiting or diarrhoea. There was no change in

her monthly menstrual flow. There was nothing remarkable in her family history. She had been to two different primary and secondary health facilities where a clinical diagnosis of uterine fibroid was made following abdominal ultrasound scanning.

General physical examination was essentially normal. The vital signs were within normal limits.

2.1 Systemic Examination

The main systemic examination findings were only found in the abdomen which revealed a pelvic mass of about 32 weeks pregnancy size. There was area of tenderness in the right and left iliac fossae. There were no vaginal masses. The adnexa were free. The gloved finger stained with clear vaginal fluid.

2.2 Laboratory Investigations

The full blood counts results were within normal limits. Serum electrolytes and creatinine were also within normal limits. Liver and renal function test results were normal. Electrocardiogram (ECG) was essentially normal.

2.3 Imaging

Abdominal Computed Tomography scan finding showed a bulky uterus with a huge mixed density mass, anterior to the uterine body and postero-superior to the urinary bladder attached to the anterior aspect of the uterine body by a short stalk, and measuring 17.9 cm, 20.7 cm and 22.5

cm in its antero-posterior, transverse and longitudinal diameters respectively with a conclusion of huge pedunculated sub-serous uterine fibroid (Figs. 1 and 2).

2.4 Intra-Operative Findings

She gave consent for exploratory laparotomy and possible hysterectomy. At surgery, a huge mass adherent to the anterior surface of the body of the bulky uterus with normal fallopian tubes and ovaries were found. The mass was completely surgically removed with a subtotal hysterectomy. The patient was clinically stable and discharged home 10 days post operation and was followed-up on out-patient gynaecology clinic basis.

2.5 Histopathology

Histopathological findings showed a huge well circumscribed mass weighing 4,200 g and measuring 21x20x11 cm (Fig. 3). Cut section showed a greyish white appearance and gritty cut surface with a cystic lesion measuring 6x 4.5 cm. Microscopy showed proliferating spindle cells that are disposed in interlacing fascicles in areas, with bland elongated nuclei and moderate eosinophilic to pale cytoplasm. Also seen are foci of hypocellular, myxoid degenerative muscle

cells, thin-walled vascular channels, perivascular lymphocytes and areas of keloid-like, collagen-like bands are seen. No nuclear atypia is seen. Overall features are those of pelvic desmoid tumour (Fig. 4).

3. DISCUSSION

Pelvic desmoid tumour is a rare mesenchymal neoplasm caused by abnormal proliferation of fibroblasts. It is generally cytologically benign and it arises from the abdominal muscle wall in postpartum women in scars due to trauma or abdominal surgery [8,9,10]. Although the aetiology is not known, the tumour is usually associated with family history, previous surgery or trauma and hormonal influence. The reported index case had no previous history of abdominal surgery or family history. Desmoid tumours are 3 times more common in women and occurs mostly between 25 and 35 years of age with peak age of 36-42 years [8,9,10]. This was consistent with our sporadic case who was a female and aged 44 years. Desmoid tumours commonly arise in the anterior abdominal wall as found in the reported case. These tumours although infiltrating into the surrounding muscular and aponeurotic structures, the overlying skin is usually spared as we have seen in this index case.

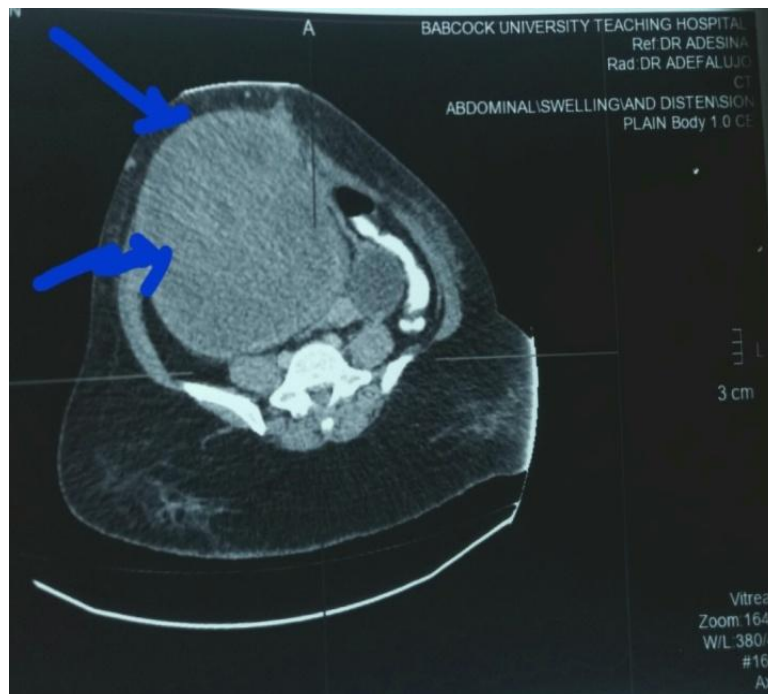


Fig. 1. Computed tomography scanogram showing huge mixed density mass

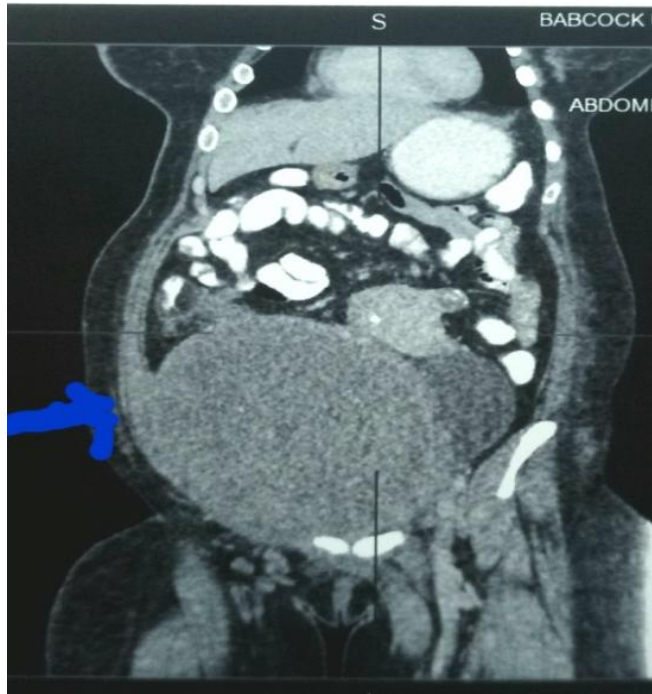

Fig. 2. Computed Tomography scanogram showing huge mixed density mass adjacent to the anterior abdominal wall

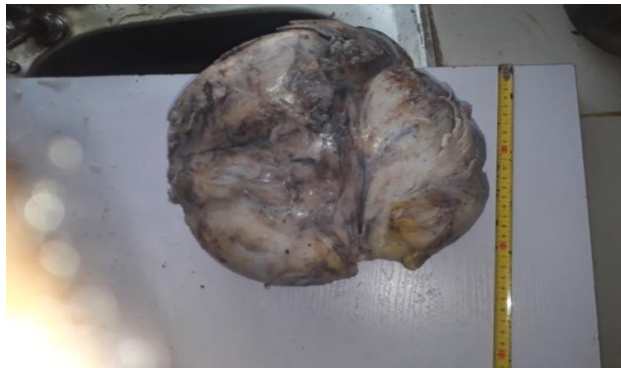

Fig. 3. Photograph of the macroscopic finding of the tumour

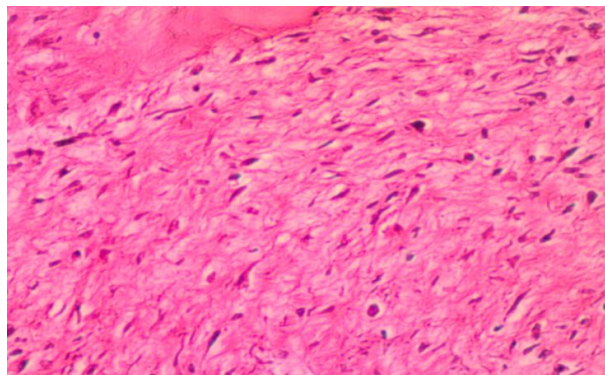


Fig. 4. Photomicrograph showing spindle cells that surround the muscle cells. These features are consistent with pelvic desmoid tumour. (Haematoxylin and eosin stain, X100)

The natural history of intra-abdominal desmoid tumours range from asymptomatic to compressive pressure symptoms in the visceral organs like intestine, bladder, ureter or nerves, which could be the initial manifestation of this condition [8,9]. The reported index case had no pressure symptoms aside abdominal swelling with mild lower abdominal discomfort.

Leiomyoma uteri is the commonest benign tumour of the female genital tract including the uterine body [11]. This perhaps makes it the first diagnostic consideration the clinician made when evaluating pelvic masses in young female adults. Its presentation varies; some studies have shown that as much as 39.1% of women with uterine fibroid present with only abdominal swelling the way our patient presented [12]. Peak age of incidence is between 30 and 40 years which compared with our patient's age at presentation [13].

Radiological investigation like Computed Tomography scan is usually used for the diagnosis but could be misleading at times [8]. This is evident in the reported case.

Surgical intervention involves the complete wide excision of the tumour which was done in the index case.

Histology of the biopsied excised tumour usually provides definitive diagnosis as in the reported sporadic case.

4. CONCLUSION

Pelvic desmoid tumour should be considered as a differential diagnosis in premenopausal women who present with abdominal swelling. Relevant clinical history, radiological imaging and histopathological assessment are essential in making prompt accurate diagnosis.

CONSENT

All authors declared that written informed institutional consent was obtained from the patient.

ETHICAL APPROVAL

It is not applicable.

COMPETING INTERESTS

Authors have declared that no competing interests exist.

REFERENCES

1. Liu X, Zong S, Cui Y, Yue Y. Misdiagnosis of aggressive fibromatosis of the abdominal wall: A case report and literature review. *Medicine*. 2018;97(10):e9925. DOI: 10.1097/MD.00000000000009925
2. Sinno H, Zadeh T. Desmoid tumors of the pediatric mandible: Case report and review. *Ann Plast Surg*. 2009;62(2):213-219.
3. Mullen JT, DeLaney TF, Kobayashi WK, Szymonifka J, Yeap BY, Chen YL et al. Desmoid tumor: Analysis of prognostic factors and outcomes in a surgical series. *Ann of Surg Oncol*. 2012;19(13):4028-4035.
4. Walczak BE, Rose PS. Desmoid: The role of local therapy in an era of systemic options. *Curr Treat Options Oncol*. 2013; 14(3):465-473.
5. Kreuzberg B, Koudelova J, Ferda J, Treska V, Spidlen V, Mukensnabl P. Diagnostic problems of abdominal desmoid tumors in various locations. *Eur J Radiol*. 2007;62(2):180-185.
6. Georgiades C, Vallianou N, Argyrakos T, Aristodimou A, Kolovelonis G, Sioula E. An unusual case of desmoid tumour presenting as haemorrhagic shock. *Ann R Coll Surg Engl*. 2012;94(2):e81-e82. DOI:10.1308/003588412X13171221588857
7. Chen CB, Chiou YY, Chen CH, Chou YH, Chiang JH, Chang CY. Sonographic and computed tomography findings of intra-abdominal desmoid tumor. *J Chin Med Assoc*. 2010;73(7):393-395.
8. Singh R, Vaishnav V, Gopal S, Yadav R. Desmoid Tumor Mimicking Uterine Leiomyoma. *JCR*. 2013;3:339-343.
9. Wu C, Amini-Nik S, Nadesan P, Stanford WL, Alman BA. Aggressive fibromatosis (desmoid tumor) is derived from mesenchymal progenitor cells. *Cancer Res*. 2010;70:7690-7698.
10. Klemmer S, Pascoe L, DeCosse J. Occurrence of desmoids in patients with familial adenomatous polyposis of the colon. *Am J Med Genet*. 1987;28:385-392.
11. Madej P, Madej JA. Pathomorphosis of uterine myomas in women. *Open Pathol J*. 2008;2:19-23.
12. Okogbo FO, Ezechi OC, Loto OM, Ezeobi PM. Uterine Leiomyomata in South Western Nigeria: A clinical study of

- presentations and management outcome. Afr Health Sci. 2011;11(2):271-278.
13. Baird DD, Dunson DB, Hill MC, Cousins D, Schectman JM. High cumulative incidence of uterine leiomyoma in black and white women: Ultrasound evidence. Am J Obstet Gynecol. 2003;188(1):100-107.

© 2020 Ajani et al.; This is an Open Access article distributed under the terms of the Creative Commons Attribution License (<http://creativecommons.org/licenses/by/4.0>), which permits unrestricted use, distribution, and reproduction in any medium, provided the original work is properly cited.

Peer-review history:
The peer review history for this paper can be accessed here:
<http://www.sdiarticle4.com/review-history/54612>