



An Interesting Case of Broken Needle

Mahapure Kiran Sunil^{1*} and Metgud Shrishail Chandrakant¹

¹Department of General Surgery, KLE Academy of Higher Education and Research, Jawaharlal Nehru Medical College, Belgaum, Karnataka, India.

Authors' contributions

This work was carried out in collaboration between both authors. Author MSC designed the study. Author MKS wrote the protocol, wrote the first draft of the manuscript and managed the literature searches. Author MSC reviewed the final manuscript. Both authors read and approved the final manuscript.

Article Information

Editor(s):

(1) Dr. N. S. Kannan, Tamil Nadu Dr. M.G.R. Medical University, India.

Reviewers:

(1) Nahida El-Rifai, Makassed General Hospital, Beirut, Lebanon.

(2) Ataman Kose, Mersin University, Turkey.

Complete Peer review History: <http://www.sdiarticle4.com/review-history/56993>

Case Study

Received 27 February 2020

Accepted 04 May 2020

Published 08 May 2020

ABSTRACT

Aims: Breakage of the needle while suturing intra-operatively is an uncommon event. The present report concerns a case presented with intra abdominal foreign body (broken curved surgical needle during tubal ligation) which was removed successfully within two hours. Sharing information like this would help to improve the prompt response to such untoward situations.

Presentation of Case: 26 years old female presented with history of Retained Foreign Body (broken needle) when she was undergoing tubal ligation in a primary health centre. The broken needle was found retrieved from the anterior rectus sheath under C-arm guidance within 2 hours with no injuries noted.

Discussion: Surgical sponge is the most common type of retained foreign body followed by other types of gauze, various plastic items/tubing, surgical instrument/retractor, needle, surgical suture material, or surgical specimen unintentionally left in place. Detailed knowledge of risk factors associated with these incidences is critical to effective preventive efforts. In addition to aggressive preventive measures, early detection and retrieval of Retained Foreign Bodies may be associated with better clinical outcomes.

Conclusion: Meticulous counting of instruments including needles and mops (as per guidelines) will help in preventing such accidents. As surgery is a team work, preventing Retained Foreign Bodies is also a team work.

*Corresponding author: E-mail: drkiranmahapure@gmail.com;

Keywords: Broken needle; retained foreign body; retained surgical instruments; tubal ligation.

1. INTRODUCTION

Breakage of the needle while suturing intra-operatively is an uncommon event. Each such incident acquires major importance because it is stressful not only for the surgeons, hospital room staff and the hospital administrator but also for the patients and relatives. Most of the times, they are retrieved and removed at the same time but in certain circumstances they may remain asymptomatic for months and years and removed incidentally. Leaving behind a foreign body can be devastating for the patient and the surgical team and also leads to medico-legal consequences [1]. The present report concerns a case presented with intra abdominal foreign body (broken curved surgical needle during tubal ligation) which was removed successfully within two hours. Sharing information like this would help to improve the prompt response to such untoward situations.

2. PRESENTATION OF CASE

26 years old female, having 2 children was undergoing Tubal ligation Procedure at a Primary Health Centre by a qualified Gynecologist under Intravenous sedation plus Local anesthesia. Prior written and informed consent was obtained. After ligation of the fallopian tubes and confirming the haemostasis, the surgeon started suturing the Rectus sheath for closure. During which he noticed that there was accidental breakage of the needle. The needle had broken at the junction of swaged end and body of the needle. The distal

two-third fragment of the needle (body and the tip of the needle) was missing while the proximal third (swaged end) was still held in the needle holder. The surgeon tried to retrieve the broken needle fragment but he could not do it. In order to avoid further furious attempts causing damage to the structures and since the radiological facilities were unavailable at the Primary Health Centre, the surgeon packed the abdominal cavity with sterile packs and closed the skin incision with tacking sutures. The patient was shifted to our institute with prior notification.

After the patient presented to our team with history of Retained Foreign Body (broken needle), she underwent quick examination and basic hemogram was sent. She was stable with blood pressure 110/70 mmHg, Pulse 128 rpm and SpO2 100%. Her Hemoglobin was 10.4 mg/dL, rest of the hemogram was normal. Without any further delay, the patient was shifted to the operation theatre where the C-arm was kept ready. On the radiogram obtained on C-arm machine, the curved broken needle fragment (Radio-opaque curved object) was seen to be on the left side and it was shown to be superficial on lateral radiogram.

Under General Anesthesia, the abdominal cavity was explored. There was no bleeding and the broken needle fragment was located embedded in the anterior rectus sheath with no injuries. On successful removal of the fragment, it was confirmed using the C-arm that there is no other fragment left behind.

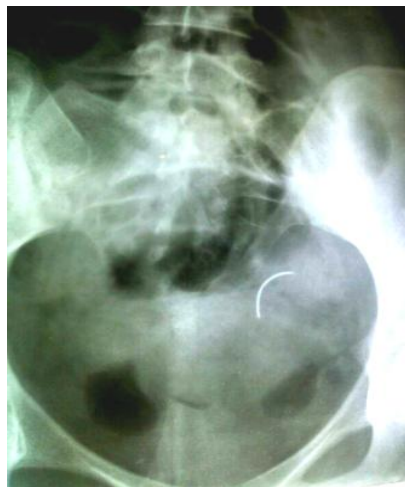

Fig. 1. Radiograph showing the broken needle fragment

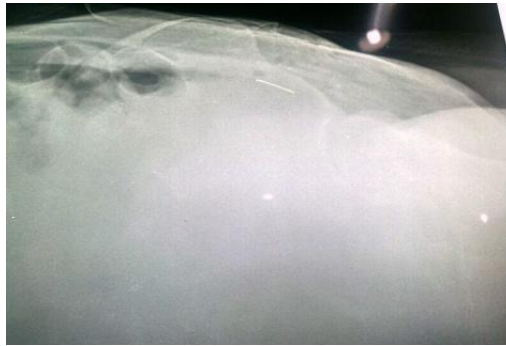


Fig. 2. Lateral radiogram

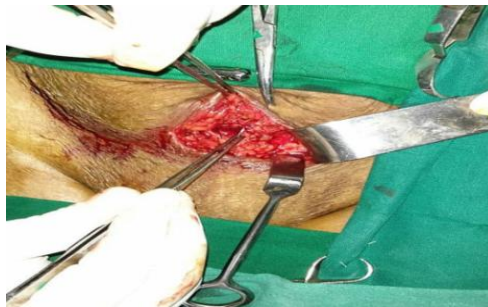

Fig. 3. Retrieval of broken needle fragment

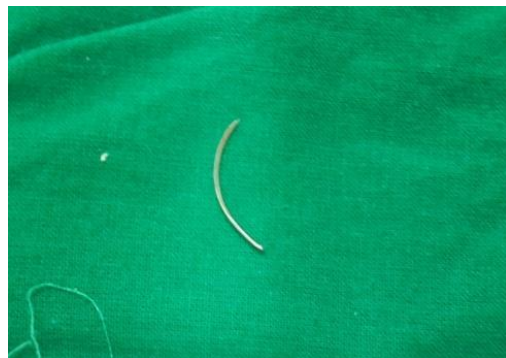

Fig. 4. Broken needle fragment

Post-operative course was uneventful. Patient discharged on 8th post-operative day. Although, patient was fit for discharge on 3rd post-operative day, the relatives of the patient requested to get discharged only after suture removal. She was followed up after one week with no complaints and healthy wound.

The whole process caused significant stress not only to the operating surgeon and his team but also to the patient and her relatives. Proper counseling of the patient and the relatives about nature of such untoward intraoperative complication and the proposed surgical management to retrieve the foreign body did help to some extent but the incidences still prove to

be distressing and chaotic about management, especially at remote places and primary health centers.

3. DISCUSSION

Surgery inherently involves the placement of foreign material inside the human body. Therefore, the risk of such material being left behind can never be fully eliminated. Breakage of a needle is an inadvertent complication and reported variedly in the literature.

Retained Surgical Instrument as a foreign object that is unintentionally retained within a patient following surgical or other

invasive procedure(s), including object(s) deliberately placed by the provider, but subsequently unintentionally left within the patient [2]. Most of the times, they are retrieved and removed at the same time but in certain circumstances they may remain asymptomatic for months and years and removed incidentally. Sometimes diagnosis of these foreign bodies is difficult, and at times, it is difficult to retrieve it particularly small object like needle [1]. Some times in a long standing cases, the foreign bodies are surrounded by gut and fistulas may occur and it may migrate to other organs like intestine, urinary Bladder etc. making retrieval difficult. Very rarely a tumour like mass forms- *Gossypiboma* (*gossybiom*, Latin for cotton; *boma*, Swahili for place of concealment) [3], also known as *gauzoma*, and *muslinoma* (from muslin, a woven cotton textile) .According to some, removal of foreign bodies like needle or small part of surgical items may cause more harm than the item itself and removal is not recommended. However, it is very difficult to translate this recommendation practically [1].

Surgical sponge is the most common type of retained foreign body followed by other types of gauze, various plastic items/tubing, surgical instrument/retractor, needle, surgical suture material, or surgical specimen unintentionally left in place [4]. In addition, there have been incidences where grasper blade of laparoscopic instrument broke and was noticed at the end of the procedure [2]. In one case report, the broken needle fragment was found in the instrument (flapper valve of the canula). In our case, the site of breakage at the junction of the distal two-thirds and proximal one-third was the site where the needle was grasped for optimal manoeuvrability, which is also similar to another case reported [1]. The cause might be repeated use more than once after sterilization, as it is still a common practise in Primary Health centres due to unavailability of enough resources. In situations of breakage of instruments less than 13 mm, there are additional considerations. These tiny bits show up very poorly on X-rays. In adults, the literature suggests a little expectation of major damage by these tiny Retained Foreign Bodies in the abdominal cavity [5].

Prevention-counting guidelines 4 separate counts are recommended: the first when the instruments are set up or sponges unpackaged before surgery begins, a second before closure of any cavity (e.g. stomach, bladder, uterus)

within the operative cavity, a third as wound closure begins (usually started at closure of the fascia), and the final count performed during skin closure. Guidelines also recommend counting on the permanent relief of either the scrub or circulating nurse [6]. The counts of the sponges should be visually available to all and are often written on dry erase boards in each operating room. New England Journal of Medicine published an article about risk factors of RFBs. Of the 8 risk factors the authors identified (emergency operation, unexpected change in operation, more than one surgical team involved, change in nursing staff during procedure, body mass index (BMI), volume of blood loss, female sex, and surgical counts) only 3 were found to be statistically significant by matched multivariate logistic regression. The 3 significant risk factors were emergency surgery, unplanned change in the operation, and BMI. Although all 3 factors were significant, the 9-fold increase in risk associated with emergency surgery was impressive [7].

Detailed knowledge of risk factors associated with Retained Foreign bodies is critical to effective preventive efforts. In addition to aggressive preventive measures, early detection and retrieval of Retained Foreign Bodies may be associated with better clinical outcomes (e.g., fewer symptoms). System-based prevention methods, including staff training and hard-wired safety procedures, must be implemented to decrease the frequency of these and other “never events” [2]. Broken instruments, if visible, ought to be retrieved. Operative field radio-opaque markers, e.g. instruments or grids during fluoroscopy, may aid in the localization of the broken instrument. Instruments, especially, those designed for multiple uses, should be checked before introducing them into the surgical field.

In spite of all precautions, such incidences do occur resulting in significant stress to the operating team with considerable sufferings of the patients [1]. In addition to direct patient harm, Retained Foreign Bodies are associated with potentially serious damage to the surgeon's and the institution's reputation. In addition, the entire healthcare system is affected because of the associated loss of trust and significant attributable expenditures. Looking beyond direct injury and the need for reoperation, such incidences result in medico-legal liability and negative public opinion toward the involved surgical personnel and the healthcare system [7]. Were the surgeon's actions in line with other surgeons'

expected actions? It is the only important factor, which decides the fate of the medico-legal cases [8].

In the above described case, even though patient's relatives were told that patient was being shifted to higher centre, they manhandled the operating team and hospital staffs, also the hospital property was damaged. As together with patient, their relatives were very much worried about the left over needle in the abdominal cavity, and also from the medico-legal point of view, removal was warranted in spite of difficulty. Worldwide Retained Foreign Bodies are regarded as a surgeon's nemesis. Despite the fact that most incidences occur in "large stakeholder" culture operation theatres, the sole legal responsibility rests with the operating surgeon. Thus, an impeccable record of surgical skills and reputation is liable to get reduced to shreds by media and peer-ridicule attributable to these tiny culprits. If the surgeon encounters breakage, and despite all efforts, it leads to a Retained Foreign Body, are the manufacturing companies completely absolved of any responsibility?

4. CONCLUSION

Retained foreign bodies can cause serious medical and legal problems. Extreme care should be taken in the maintenance of surgical instruments. Meticulous counting of instruments including needles and mops (as per guidelines) will help in preventing such accidents. As surgery is a team work, preventing Retained Foreign Body is also a team work, every member in the team including nurses should make conscious effort in this direction abiding recommendations more so in high risk cases. Thereby preventing mortality and morbidities of the patients and avert litigations.

CONSENT

It is not applicable.

ETHICAL APPROVAL

It is not applicable.

COMPETING INTERESTS

Authors have declared that no competing interests exist.

REFERENCES

1. Das C, Mukherjee G, Pati S, Naskar A. Missing broken needle during caesarean section. *Online J Health Allied Scs.* 2009;8(2):12.
2. Sanfilippo JS, Smith SR, Pruitt SM. Lost needle tip during hysterectomy. *OBG Manag.* 2015;27(3):41–44.
3. Whang G, Mogel GT, Tsai J, Palmer SL. Left behind: Unintentionally retained surgically placed foreign bodies and how to reduce their incidence--pictorial review. *AJR Am J Roentgenol.* 2009;193(6 Suppl):S79–S89. DOI:10.2214/AJR.09.7153
4. Mirsharifi R, Aminian A, Jafarian A, Kalhor M, Dashti H, Ali FAH, et al. Answer to clinical quiz of the previous issue: Retained foreign body, Brief Review. *Shiraz E Med J.* 2008;9(4):201-204.
5. Styskel B, Wernick B, Mubang RN, Falowski SM, Papadimos TJ, Stawicki SP. Retained surgical items: Building on cumulative experience. *Int J Acad Med.* 2016;2(1):5-21.
6. Parelkar SV, Sanghvi BV, Shetty SR, Athawale H, Oak SN. Needle in a haystack: Intraoperative breakage of pediatric minimal access surgery instruments. *J Postgrad Med.* 2014;60(3):324- 326.
7. Liu ZH, Wang HD, Xu X, Man LB. Removal of a broken acupuncture needle in retroperitoneum by laparoscopy: A case report. *BMC Surg.* 2019;19(1):102. DOI: 10.1186/s12893-019-0572-y
8. Smith BM, Brown RA, Lobe TE. The lost needle: A laparoscopic dilemma. *J Laparoendosc Surg.* 1993;3(4):425-6. DOI:10.1089/lps.1993.3.425

© 2020 Mahapure and Metgud; This is an Open Access article distributed under the terms of the Creative Commons Attribution License (<http://creativecommons.org/licenses/by/4.0>), which permits unrestricted use, distribution, and reproduction in any medium, provided the original work is properly cited.

Peer-review history:

The peer review history for this paper can be accessed here:
<http://www.sdiarticle4.com/review-history/56993>