

## Lurbinectidin, an Anticancer Drug of Natural Origin, Effectively Reduces Retinal Macular Edema: A Case Report

Feliciano Menna<sup>1\*</sup>, Filippo Simona<sup>1</sup>, Alessandro Meduri<sup>2</sup>, Stefano Lupo<sup>3</sup>  
and Francesco Bandello<sup>4</sup>

<sup>1</sup>Centro Oculistico PAX, Locarno, Switzerland.

<sup>2</sup>Department of Ophthalmology, Surgical Specialities, University of Messina, Messina, Italy.

<sup>3</sup>Department of Ophthalmology, University of Rome Sapienza, Polo Pontino, Terracina, Italy.

<sup>4</sup>Division of Head and Neck, Ophthalmology Unit, IRCCS San Raffaele Scientific Institute, Vita-Salute San Raffaele University, Milan, Italy.

### Authors' contributions

This work was carried out in collaboration among all authors. Authors FS and FB designed the study, wrote the protocol and wrote the first draft of the manuscript. Author FM managed the analyses of the study. Authors SL and AM managed the literature searches. All authors read and approved the final manuscript.

### Article Information

#### Editor(s):

(1) Dr. Panagiotis Tsikripis, University of Athens, Greece.

#### Reviewers:

(1) Ștefan Țălu, The Technical University of Cluj-Napoca, Romania.

(2) Tayo Julius Bogunjoko, Eye Foundation Hospital Group, Nigeria.

Complete Peer review History: <http://www.sdiarticle4.com/review-history/56485>

Case Study

Received 23 February 2020

Accepted 29 April 2020

Published 11 May 2020

### ABSTRACT

**Purpose:** To describe a case of macular edema, secondary to thrombosis, reduced during the oral treatment with lurbinectidin.

**Methods:** Patient affected by central macular edema to the right eye, due to central venous thrombosis, in chemotherapy for a small cell lung cancer with lurbinectidine. Lurbinectidine is a natural marine molecule isolated from the Caribbean algae "*Ecteinascidia turbinata*", used clinically and approved for the treatment of advanced soft tissue sarcoma. The patient was treated with five chemotherapy sessions of lurbinectidine from October 2018 to May 2019 and we compared the central macular thickness before and after each chemotherapy session and performed OCT progression analysis using the CIRRUS Zeiss software.

\*Corresponding author: E-mail: feliciano.menna@gmail.com;

**Results:** A strict cause-effect relationship between therapy and disappearance of edema was noted. We showed an improvement in macular edema in relation to the patient's chemotherapy sessions for therapy of small cell lung cancer.

**Discussion:** We think that this case demonstrates the anti-edema action of Lurbinectidin in maculopathy without any side effects.

*Keywords: Lurbinectidin; macular edema; natural anticancer drugs.*

## 1. INTRODUCTION

With the introduction in the clinical practice of drugs inhibiting vascular endothelial growth factor (VEGF) the visual outcomes of patients with neovascular age related macular degeneration (AMD) dramatically improved. Since 2006 repeated intravitreal injections of anti-VEGF became the standard of care for the treatment of neovascular AMD. Several questions remain open, in particular the regimen of treatment, the frequency of injection, the safety of the different drugs, and the poor response to the treatment in some cases [1].

In 2004, Avastin (bevacizumab), a monoclonal antibody used for the treatment of colorectal cancer, of breast and lung cancer, comes into play. This molecule inhibits the VEGF protein, an acronym for the Vascular Endothelial Growth factor, which, as the name implies, stimulates the formation of new vessels [2,3].

The idea of trying bevacizumab for AMD came to dr. Philip Rosenfeld at the Bascom Palmer Eye Institute in Miami. After two or three systemic infusions of 5.0 mg/kg bevacizumab at two weeks, the macular fluid had disappeared and the vision improved in all 18 patients studied, lasting 6 months or more at 12 [4].

In search of a lower dose and a reduction in cardiovascular risks, Dr. Rosenfeld has had another revelation. A 2004 article by Dennis P Han MD showed that antibodies injected intravitreally penetrate the retina [5].

Dr. Rosenfeld, with the help of the pharmacist Serafin Gonzalez, found that bevacizumab was also suitable for intravitreal injection (0.05 mg).

There are several anti-VEGF drugs currently used for the treatment of senile macular degeneration, but three are the most commonly used for the condition: ranibizumab (Lucentis® brand), aflibercept (Eylea® brand), designed specifically for the treatment of AMD and bevacizumab (trade name Avastin®), originally

developed to treat various types of cancer, but is commonly used "off-label" in patients with AMD.

Although there are many clinical trials comparing the advantages and disadvantages of the three drugs (Avastin, Eylea and Lucentis), the growing collective experience of ophthalmologists indicates that all three are effective treatments for wet macular degeneration [6,7].

The therapy involves the intraocular injection of the substance which, spreading in the vitreous body and in the thickness of the retina, comes into contact with the CNV, where it essentially exercises a series of effects characterized by:

- Inhibition of growth and extension of the neovascular process.
- Regression of neovascularization.
- Stabilization of the endothelial membranes and decrease in the degree of permeability in the CNV microcirculation.
- Reduction of the diffusion intensity of protein and lipid molecules in extravascular spaces, reduction of edema and normalization of central macular retinal thickness [8].

For these described effects, anti-VEGFs are used not only in the treatment of exudative age-related macular degeneration, but also in diabetic macular edema and in macular edema secondary to thrombosis of the retinal vessels [9,10].

## 2. CASE REPORT

We report the case of a 70-year-old gentleman with an ocular history characterized by a central macular edema to the right eye, due to central venous thrombosis, in chemotherapy for a small cell lung cancer with a new substance, lurbinectidine, which showed to have a positive effect also on the edema absorption, without any side effect.

The first control performed on 18 July 2018 at our practice presented the following ocular functional data:

Visual acuity with correction OD 7/10 (not improved) OS 10/10

IOP OD 12 mmHg OS 13 mmHg

He reported to the general anamnesis that he was in chemotherapy for a small cell lung cancer with a new substance, lurbinectidine, still in phase 2 of clinical experimentation (PM1183-B-005-14). A year ago, when he was diagnosed with cancer, he was treated with cisplatin but with no results.

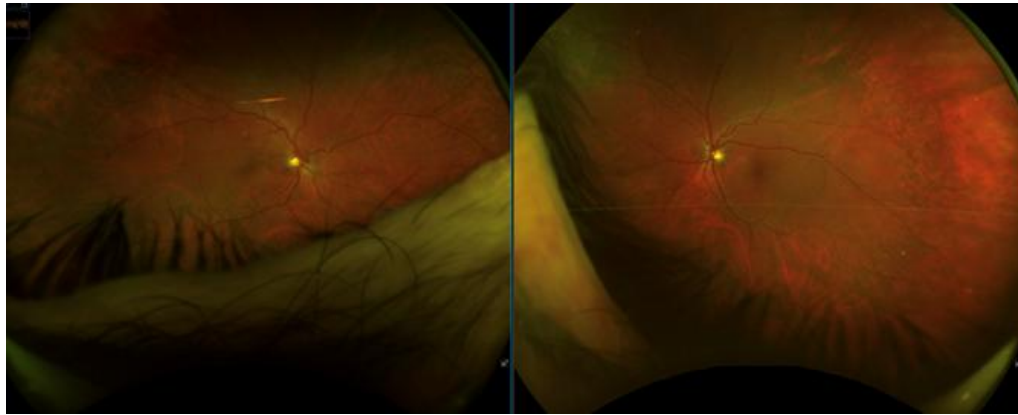


Fig. 1. Fundus photo: On the left side the fundus photo of the right eye, on the right side the fundus photo of the left eye

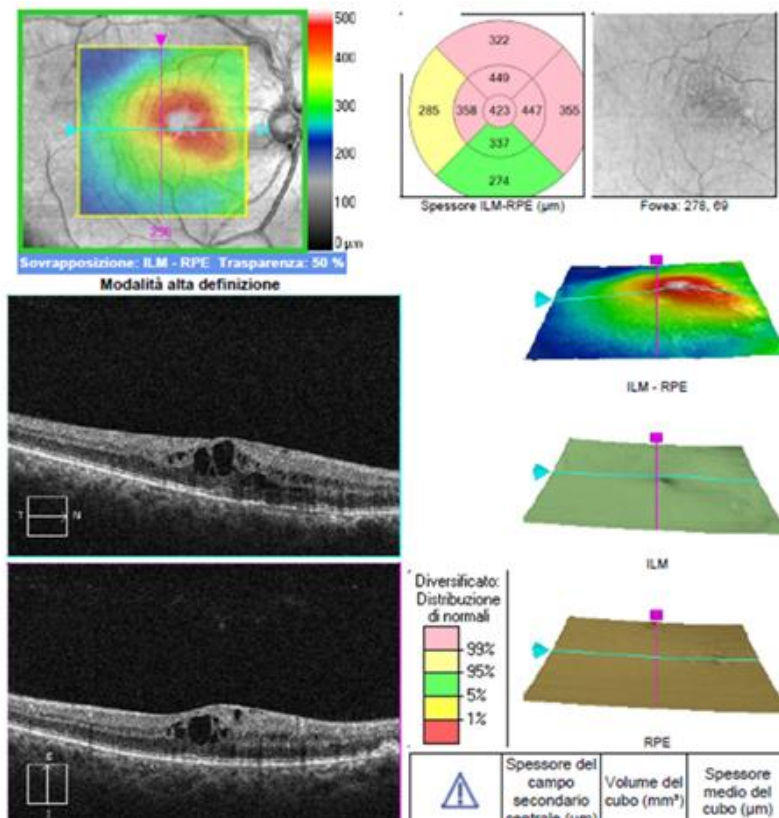
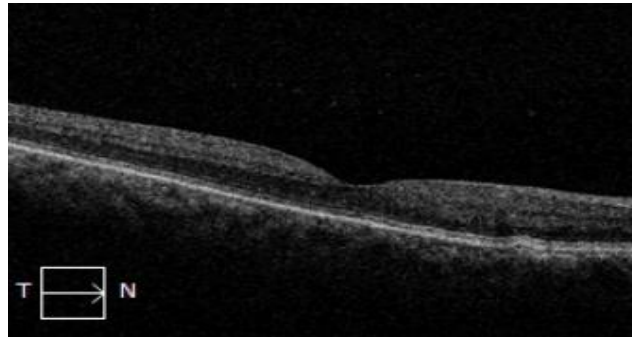


Fig. 2. OCT of the right eye at first control

On November 14, 2017 has been diagnosed the central macular edema to the right eye and it was treated with three Lucentis injections carried out on December 14, 2017, February 14, 2018 and March 27, 2018, not by us but elsewhere.

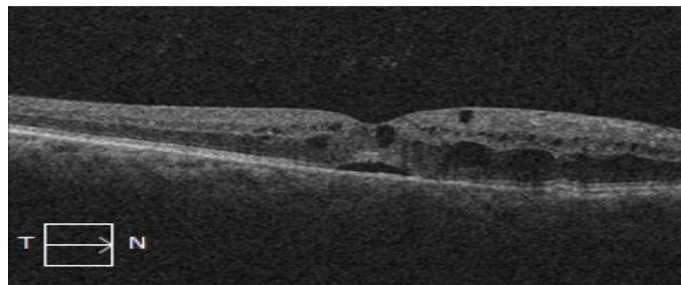
Based on the OCT (Fig. 2), a fourth Lucentis injection is programmed.

On August 21, 2018 the patient came back to us and an OCT was carried out before the fourth Lucentis injection (Fig. 3). The exam, compared to the previous one (Fig. 2), without explanation shows the complete absorption of edema and the reduction of the central field thickness to 213  $\mu\text{m}$ .

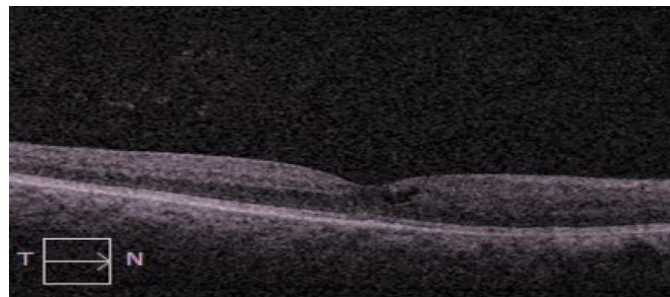


**Fig. 3. OCT of the right eye performed on August 21, 2018**

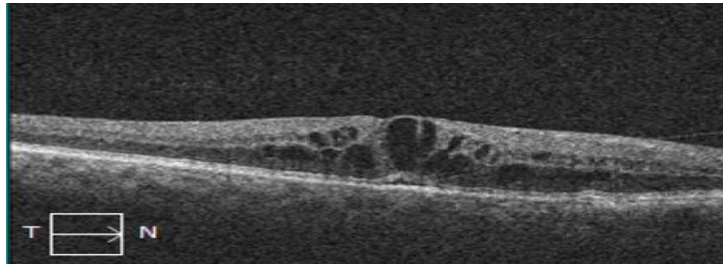
At this point we contact the oncologist of the patient in question and we learn that the patient had a chemotherapy session with Lurbinectidine. However, the oncologist advises against injecting Lucentis intravitreal. For this reason we limit ourselves to keeping the patient under control and to carry out periodic monthly checks precisely because of the peculiarity of the clinical case. Surprisingly we see an improvement in macular edema in relation to the chemotherapy sessions carried out by the patient, as shown below:



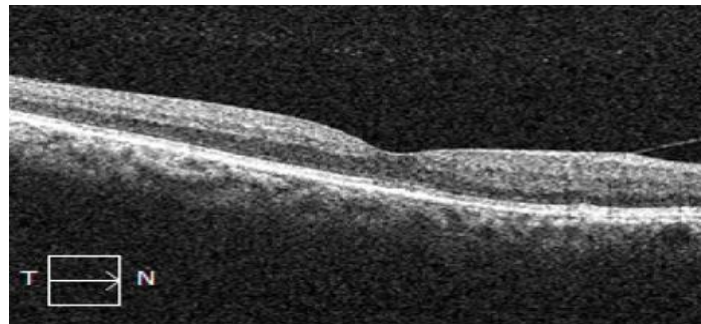
**11 October 2018 - before the treatment with lurbinectidine: The central thickness is 413  $\mu\text{m}$**



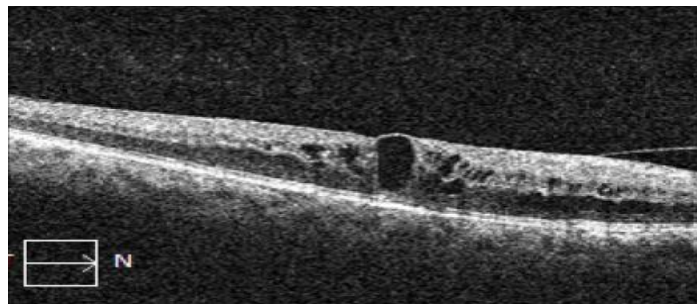
**27 November 2018 - after the chemotherapy performed on October 16<sup>th</sup>: The thickness is reduced to 300  $\mu\text{m}$**



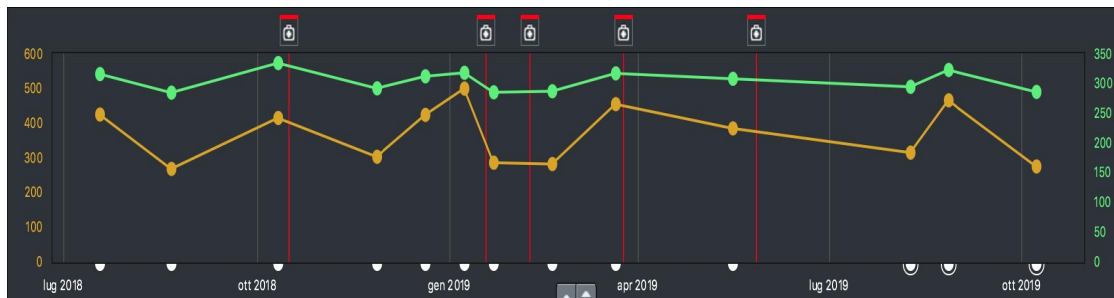
8 January 2019 - the edema with a central thickness of 496 μm reappears



22 January 2019 - after the chemotherapy performed on January 18<sup>th</sup>: the edema appears to be reabsorbed and the thickness reduced to 284 μm



21 March 2019 - before the chemotherapy scheduled for 25 March: the edema reappears and the thickness increased to 449 μm



**Fig. 4. OCT progression analysis. Red lines: Chemotherapy sessions with lurbinectidine (16.10.2018, 18.1.2019, 8.2.2019, 25.3.2019, 27.5.2019); Green line: The central secondary field; Yellow line: The average cube thickness. Note the decrease of the edema after the chemotherapy sessions**

### 3. DISCUSSION

Lurbinectidine is a natural marine molecule isolated from the Caribbean algae "*Ecteinascidia turbinata*", used clinically and approved for the treatment of advanced soft tissue sarcoma. Mechanically, this agent exhibits potent anti-proliferative activity by covalently binding to small DNA grooves that induce rupture in double-stranded DNA, thus leading to cellular apoptosis. Lurbinectidine is in phase II clinical trials for the treatment of small cell lung cancer, hereditary breast [11] and ovarian [12] and uterus cancers [13].

Lurbinectidine belongs to the category of alkaloids of marine origin. It is structurally related to trabectedin, from which however it differs in the C ring due to the presence of a tetrahydro- $\beta$ -carboline instead of a tetrahydroisokinoline. The alkaloids of marine origin are part of the large class of chemotherapeutic drugs with antimitotic action of natural origin, including vincristine, already known for its effective action in the treatment of retinoblastoma [14].

The alkaloids, like the taxanes, interrupt the division of the cell for the modification of the microtubule dynamics. The alkaloids act by causing the inhibition of tubulin polymerization in microtubules, with consequent arrest in the G2/ M phase within the cell cycle and cell death.

The alkaloids are substances that the plant produces from amino acids and are probably synthesized for defensive purposes or deriving from the metabolism of toxic substances or for growth and as sources of nitrogen. In fact, as regards their function in the plant, different opinions are found in the literature. Some authors attribute to these molecules a detoxifying action for the plant cell, in the sense that with them substances harmful to the plant are eliminated; others attribute them a reserve function of nitrogenous substances and protect them from external agents. These compounds contain basic nitrogen and have been used by man since ancient times, having effects such as codeine and morphine of the narcotic and sedative type.

The anti-inflammatory action has already been scientifically proved for the equivalent

compound, trabectedin [15] but cases on the positive effect of lurbinectidine on macular edema of rare origin, also vascular, have not yet been described.

In the field of natural anticancer agents in relation to ocular pathologies, only the action of Fucoïdan, a sulfated polysaccharide with a high content of L-fucose, which can be extracted from brown algae and marine invertebrates, has been described. The study, conducted on retinas of diabetic mice, showed that the fucoïdan downregulates the HIF-1 $\alpha$ /VEGF signaling pathway and also showed a reduction in VEGF expression even after combined use of fucoïdan and bevacizumab [16].

The alkaloids have many characteristics that make them interesting substances for the treatment of the main disabling diseases such as diabetic retinopathy and age-related macular degeneration. It is possible that they can protect against oxidative stress and reduce VEGF activity.

### 4. CONCLUSIONS

This case demonstrates the anti-edema action of Lurbinectidine in maculopathy.

To further investigate lurbinectidine in this field, a thorough investigation of lurbinectidine bioactivity must be undertaken to identify the most promising candidate for preclinical and clinical tests, to understand whether these compounds can be used locally and to avoid unwanted serious adverse events such as in the case of Fingolimod used in multiple sclerosis which was associated with the possibility of onset of macular edema following its administration [17].

The hypothesis could therefore be to use both monoclonal antibodies and alkaloids of marine origin or eventually exploit their synergism to develop new successful therapeutic perspectives.

### CONSENT AND ETHICAL APPROVAL

The study and protocol have been approved by the Clinical Research Ethics Committee. According to this law and the Declaration of Helsinki informed consent was obtained.

## COMPETING INTERESTS

Authors have declared that no competing interests exist.

## REFERENCES

1. Eandi C, Alovise C, De Sanctis U, Grignolo F. Treatment for neovascular age related macular degeneration: The state of the art. *European Journal of Pharmacology*. 2016; 787(15):78-83.
2. Simona-Delia Țălu, Ștefan Țălu, Use of OCT Imaging in the diagnosis and monitoring of age related macular degeneration. In age related macular degeneration – The recent advances in basic research and clinical care. Edited by: Dr. Gui-Shuang Ying, University of Pennsylvania School of Medicine, United States of America. Published by In Tech, Janeza Trdine 9, 51000 Rijeka, Croatia. 2012;300. [ISBN: 978-953-307-864-9]
3. Ștefan Țălu, Multifractal geometry in analysis and processing of digital retinal photographs for early diagnosis of human diabetic macular edema. In: *Current Eye Research*, published by Taylor & Francis. 2013;38(7):781-792. DOI: 10.3109/02713683.2013.779722
4. Ferrara N, Hillan KJ, Gerber HP, Novotny W. Discovery and development of bevacizumab, an anti-VEGF antibody for treating cancer. *Nat Rev Drug Discover*. 2004;3(5):391-400.
5. Michels S, Rosenfeld P, Puliafito C, Marcus E, Venkatraman A. Systemic bevacizumab (Avastin) therapy for neovascular age-related macular degeneration twelve-week results of an uncontrolled open-label clinical study. *Ophthalmol*. 2005;112(6):1035-1047.
6. Dennis P. Intravitreal human immune globulin in a rabbit model of staphylococcus aureus toxin-mediated endophthalmitis: A potential adjunct in the treatment of endophthalmitis. *Trans Am Ophthalmol Soc*. 2004;102:305-320.
7. Böhni S, Bittner M, Howell J, Bachmann L, Faes L, Schmid MK. Comparison of Eylea® with Lucentis® as first-line therapy in patients with treatment-naïve neovascular age-related macular degeneration in real-life clinical practice: retrospective case-series analysis. *BMC Ophthalmology*. 2015;15:109.
8. Peyman Gholam A, Moshfeghi D. Intravitreal injection of therapeutic agents. *Retina*. 2009:875-912.
9. Schauwvlieghe AME, Dijkman G, Hooymans JM, Verbraak FD, Hoyng CB, Dijkgraaf MGW, Peto T, Vingerling JR, Schlingemann RO. Comparing the effectiveness of bevacizumab to ranibizumab in patients with exudative age-related macular degeneration. *The BRAMD Study. Plos One*. 2016;11(5): e0153052.
10. David M. Brown, Peter A. Campochiaro, S. Gray. Ranibizumab for macular edema following central retinal vein occlusion: Six-month primary end point results of a phase iii study. *Ophthalmology*. 2013;120(7): 1507-1508.e2.
11. Cruz, Llop-Guevara, Garber, Arun, Serra. Multicenter Phase II Study of Lurbinectedin in BRCA-Mutated and Unselected Metastatic Advanced Breast Cancer and Biomarker Assessment Substudy. *J Clin Oncol*. 2018;36(31):3134-3143
12. Vidal, Muñoz C, Guillén MJ, Moretó J, Puertas S, Martínez-Iniesta M, Figueras A. Lurbinectedin (PM01183): A new DNA minor groove binder, inhibits growth of orthotopic primary graft of cisplatin-resistant epithelial ovarian cancer. *Clin Cancer Res*. 2012;18(19):5399-411.
13. Yokoi, Mabuchi, Shimura. Lurbinectedin (PM01183): a selective inhibitor of active transcription, effectively eliminates both cancer cells and cancer stem cells in preclinical models of uterine cervical cancer. *Invest New Drugs*. 2019;37(5): 818-827.
14. Malik RK, Friedman HS, Djang WT, Falletta JM, Buckley E, Kurtzberg J, Kinney TR, Stine K, Chaffee S, Hayes J, et al. Treatment of trilateral retinoblastoma with vincristine and cyclophosphamide. *Am J Ophthalmol*. 1986;102(5):650-6.
15. Allavena P, Signorelli M, Chieppa M, Erba E, Bianchi G, Marchesi F, Olimpio CO, Bonardi C. Anti-inflammatory properties of the novel antitumor agent yondelis (trabectedin): Inhibition of macrophage differentiation and cytokine

- production. *Cancer Res.* 2005;65(7):2964-71.
16. Klettner. Fucoidan as a Potential Therapeutic for Major Blinding Diseases-- A Hypothesis. *Mar Drugs.* 2016;14(2).
17. Sudha Cugati MS, PhD, Celia S. Chen, Stewart Lake, Andrew W. Lee. Fingolimod and macular edema. Pathophysiology, diagnosis, and management. *Neurol Clin Pract.* 2014;4(5):402–409.

---

© 2020 Menna et al.; This is an Open Access article distributed under the terms of the Creative Commons Attribution License (<http://creativecommons.org/licenses/by/4.0>), which permits unrestricted use, distribution, and reproduction in any medium, provided the original work is properly cited.

*Peer-review history:*  
*The peer review history for this paper can be accessed here:*  
<http://www.sdiarticle4.com/review-history/56485>