

# CASE REPORT

## PRIMARY CENTRAL NERVOUS SYSTEM LYMPHOMA

**Anvari S.S. MD<sup>1</sup>**  
**Karimzadeh P. MD<sup>2</sup>,**  
**Tonekaboni S.H. MD<sup>2</sup>,**  
**Mahvelati F. MD<sup>3</sup>,**  
**Khatami A.R. MD<sup>4</sup>,**  
**Gharib A. MD<sup>5</sup>,**  
**Nazari Sh. MD<sup>6</sup>,**  
**Farzan M. MD<sup>7</sup>,**  
**Ghofrani M. MD<sup>8</sup>**

1. Fellowship of Pediatric Neurology, Shahid Beheshti University of Medical Sciences
2. Pediatric Neurologist, Associate Professor, Pediatric Neurology Research Center, Shahid Beheshti University of Medical Sciences
3. Pediatric Neurologist, Assistant Professor, Pediatric Neurology Research Center, Shahid Beheshti University of Medical Sciences
4. Radiologist, Assistant Professor, Shahid Beheshti University of Medical Sciences
5. Pathologist, Assistant Professor, Shahid Beheshti University of Medical Sciences
6. Pediatric Hematologist & Oncologist, Assistant Professor, Shahid Beheshti University of Medical Sciences
7. Neurosurgeon, Assistant Professor, Shahid Beheshti University of Medical Sciences
8. Professor of Pediatric Neurology, Pediatric Neurology Research Center, Shahid Beheshti University of Medical Sciences

Corresponding Author:  
Karimzadeh P. MD  
Mofid Children Hospital  
Tel: +98 21 22909559  
Fax: +98 21 22909559  
Email: pkarimzadeh@yahoo.com

Received : 05-01-2009,  
Last revised: 09-02-09,  
Accepted: 10-06-09

### Abstract

#### Objective

Primary central nervous system lymphoma (PCNSL) is an extremely rare condition in childhood. We report the first case of PCNSL in a child in Iran.

#### Clinical presentation

A nine-year-old boy was referred to Mofid Hospital with the history of headache of four months and seizure of 2 months duration. Magnetic resonance imaging of the brain revealed a hyper-intense lesion in left fronto-parietal area with secondary satellite lesions.

Biopsy of the brain mass was performed. Pathologic findings showed brain lymphoma and immunohistochemistry confirmed this diagnosis. The treatment started with intrathecal and systemic chemotherapy in combination with radiotherapy.

**Keywords:** Lymphoma, Primary central nervous system lymphoma (PCNSL), Children

### Introduction

Primary central nervous system lymphoma (PCNSL) is an uncommon condition in children and accounts for approximately 1% to 3% of all central nervous system malignancies (1,2,3,7). It is actually an extranodal non-hodgkin's lymphoma (NHL) arising from the brain parenchyma, eyes, meninges, or spinal cord in the absence of systemic disease (2).

In immunocompetent patients, mean age of PCNSL diagnosis is 53 to 57 years, with a male to female ratio of 1.2 – 1.7 to 1 (5). Among AIDS patients, mean age of the disease presentation is younger (31 to 35 years). Primary central nervous system lymphoma has been diagnosed in HIV-positive children as young as 2 years (5). Immunocompromised patients are at the particular risk for developing PCNSL such as individual affected with human immunodeficiency virus (HIV), receiver of organ transplantation, or sufferer of congenital immunodeficiency syndromes. In this setting, PCNSL is due to Epstein-bar virus (EBV). Affected B cells, proliferate without the controlling effect of the immune system and tend to form tumors. The fact of how these neoplasms exactly develop in the central nervous system is a mystery (3). The signs and symptoms of PCNSL at presentation reflect the neuroanatomic location of the lesions. The condition presents in four distinct anatomic distributions in both immunocompetent and patients with acquired immunodeficiency syndrome (AIDS):

- 1- Solitary or multiple, discrete or diffuse intracranial mass lesions.

2- Leptomeningeal lesions.

3- Ocular lymphoma with or without other lesions.

4- Rare spinal cord lesions (5).

As far as neuroimaging evaluation is concerned, in a retrospective series of immunocompetent patients with PCNSL, the patients presented more often with a single brain lesion, either supratentorial (87%), and involvement of the frontoparietal lobes (39%) (4). In immunocompetent patients, the most common presentations included focal neurologic deficits (56% to 70%), mental status and behavioral changes (32% to 43%), symptoms and signs of increased intracranial pressure [headaches, nausea, vomiting, and papilledema (32% to 33%)], and seizures (11% to 14%) (4). Multiple lesions are seen in 30% to 40% of the cases. The average period between the onset of the symptoms and the diagnosis of PLCNS is 3 months in immunocompetent and 2 months in patients with AIDS. Administration of corticosteroids can delay the diagnosis (5).

In immunocompetent patients, a solitary lesion infiltrating the corpus callosum, enhancing homogeneously, and associated with only a moderate amount of edema is highly suggestive of PCNSL. However, in addition to PCNSL, the radiographic differential diagnoses of a single homogeneously enhancing lesion surrounded by edema include glioma, metastatic brain tumor, and focal demyelinating lesion. Diffuse periventricular involvement without a discrete mass is a less common presentation of PCNSL and may be mistaken with multiple sclerosis. For AIDS patients, differential diagnoses of multiple ring-enhanced lesions on CT or MRI include PCNSL and toxoplasmosis cerebri. These have a similar radiographic appearance on CT and MRI and a similar prevalence in AIDS patients (5).

Masses are commonly isodense or hyperdense on CT and homogeneously enhanced after the administration of intravenous contrast. On MRI, most lesions are hypointense on T1-weighted images, isotense or hyperintense on T2-weighted images, and enhance moderately to markedly after gadolinium administration (5), which tends to demonstrate a commonly deep or periventricular supratentorial mass (3). Brain biopsy, lumbar puncture for cerebrospinal fluid (CSF) cytology, or vitrectomy

can be used to establish tissue diagnosis (3).

### Case Report

Our patient was a 9-year-old boy from a nonconsanguineous healthy parents and low socioeconomic class. He was born after an uneventful pregnancy and delivery. The patient's weight, height, and head circumference were 18 kilograms (< 5th percentile), 116 centimeters (<5th percentile), and 49 centimeters (~ 5th percentile) respectively. His uncle and aunt had died at the age of 2 and 10 due to diarrhea. His sister had also died of unknown cause when she was seven months. At the age of seven months, the patient was evaluated for chronic diarrhea, recurrent fever, and periodic vomiting. He was taken repeatedly to the hospital for these problems. After starting diarrhea, the process of weight gain slowed down. At 4 year of age, he had his last admission, and after that, severity of the diarrhea and vomiting decreased.

Four months before referring to our center, he presented with episodes of headaches in the frontal region and depression. The first seizure presented two months after the start of headache and the second seizure was one month later. The type of seizure was generalized tonic-clonic with upward gaze. After initiation of the headache, he lost 4 kilograms of this weight. At admission, he was afebrile and his vital signs were normal.

Cranial nerve examination and mental status were normal. In laboratory tests, complete blood count, sodium, potassium, blood sugar, calcium, blood urea nitrogen, creatinine, liver function tests, albumin, electrolytes, antiendomysial antibody (IgA), and gliadin antibody (IgG) were within normal limits. The level of erythrocyte sedimentation rate was 25 and C-reactive protein was negative. In flow-cytometry, CD4 was 9% and CD4 /CD8 0.16 (normal, 1/2 ). HIV Ab was negative.

Regarding the risk of herniation, lumbar puncture was not performed. In immunologic assessment, except for IgM, other immunoglobulins were decreased.

Gastroduodenoscopy had been performed three times before the age 4 due to recurrent and chronic diarrhea, but the assessment revealed no significant

diagnosis. Bone marrow aspiration, abdomino-pelvic ultrasonography and bone survey were normal. Also, spiral CT of abdomen and pelvis and axial spiral CT of chest with contrast media were normal. Brain MRI showed a mass in the left frontoparietal lobe, secondary satellite lesion, and another mass in the posterior fossa. The patient then underwent biopsy of brain mass. Pathologic evaluation revealed neoplasm sheets of typical lymphoid cells with a predominantly vasocentric growth pattern, exhibiting a B cell immunophenotype. Immunohistochemically, the neoplastic cells labeled for Leukocyte Common Antigen (LCA) , CD20, and CD79a, revealed negative staining for Glial Fibrillary Acid Protein (GFAP), synaptophysin and CD3. These findings were consistent with PCNSL- diffuse large B cell type .

### Discussion

Approximately, 75 percent of the patients with PCNSL have advanced HIV disease. Initial symptoms and signs may be variable including seizures, headache, and /or focal neurologic dysfunction. However, subtle behavioral changes may be the only complaint (6). Primary central nervous system lymphoma is an extranodal non-Hodgkin lymphoma arising from neuraxis. It represents about 3% to 4% of all primitive brain neoplasms and is mainly located in deep supratentorial regions (1).

Primary lymphoma of the central nervous system is a rare condition, especially in children (1,2,7,8,9,10). It is thought to arise from indigenous brain histiocytes (microglia) or rare lymphocytes that are normally in the meninges and around the vessels. Mostly, these lymphomas affect the immunosuppressed individuals such as AIDS patients. But, they can also develop in those with intact immune system. Cerebral lymphomas are poorly defined tumors with necrosis (very similar to glioblastomas). Spread to meninges is very common, and some of them arise from subarachnoid space. Cerebral lymphomas are highly malignant (11).

Metastases to brain and meninges from systemic malignancies are rare in childhood. The exceptions to this rule are childhood leukemia and lymphoma involving the brain. They appear on CT as areas of

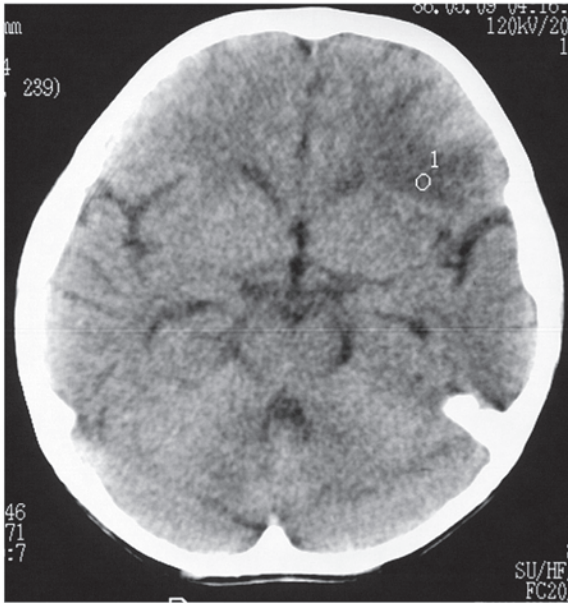
isodense or hyperdense before contrast (12).

The classic type of primary brain lymphoma in patients with normal immunity is a solitary homogeneous enhancing mass (13-15). Enhancement patterns differ between the immunocompetent and immunocompromised patients (16). In immunocompetent patient, un-enhanced CT typically shows a high-density lesion (70%) in a central hemispheric location, often reaching or crossing the midline. Hemorrhage within the tumor is rare, although it is more common in lymphoma associated with AIDS. Classic findings of a space-occupying lesion, including mass effect and surrounding vasogenic edema are seen on imaging studies of primary brain lymphoma in more than half of the patients (17). A cerebral mass is detected in a supratentorial parenchymal location involving the corpus callosum, basal ganglia, and other deep cerebral nuclei in immunocompromised patients. Contrast enhancement is variable (commonly, an inhomogeneous or bizarre pattern). Solitary ring-enhancement is more likely to be seen in this group (18,19). In view of bizarre inhomogeneous enhancement of right side lesion and ring-like enhancement of the left side, we conclude, that our immunocompromised patient suffered from a primary brain lymphoma.

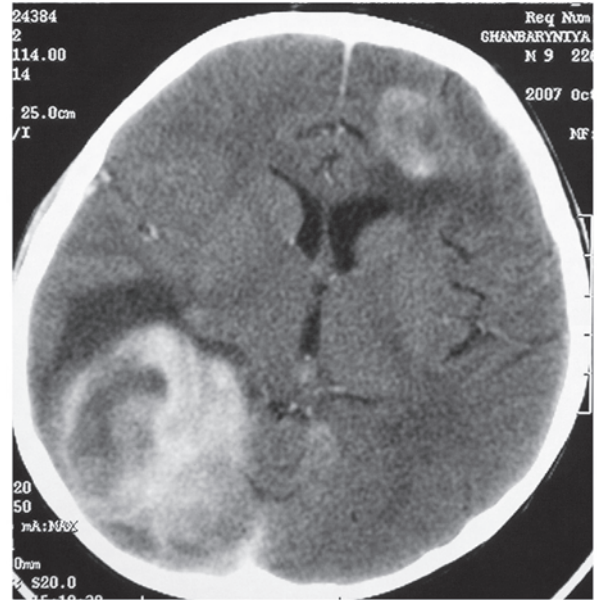
In conclusion,

- Primary CNS lymphoma might be seen in childhood, although it is very rare.
- Headache and seizure may be the symptoms of a serious disease; therefore, careful assessment is necessary.
- The patients with PCNSL might have several masses in the brain (supratentorial and /or infratentorial).
- Chronic diarrhea and failure to thrive are significant signs of immunodeficiency disorders.

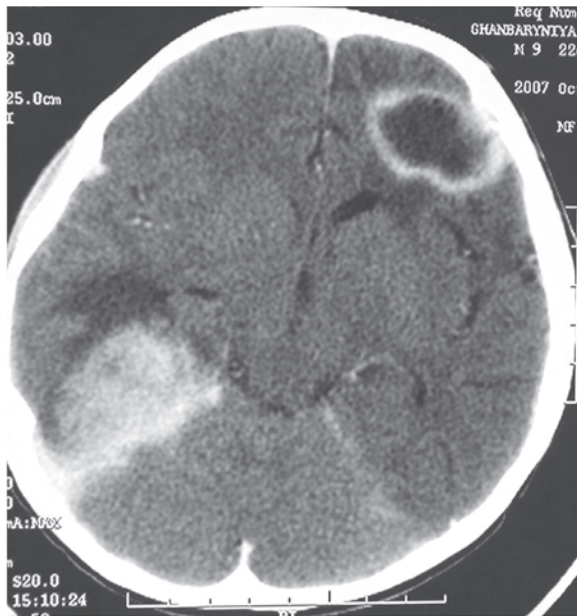




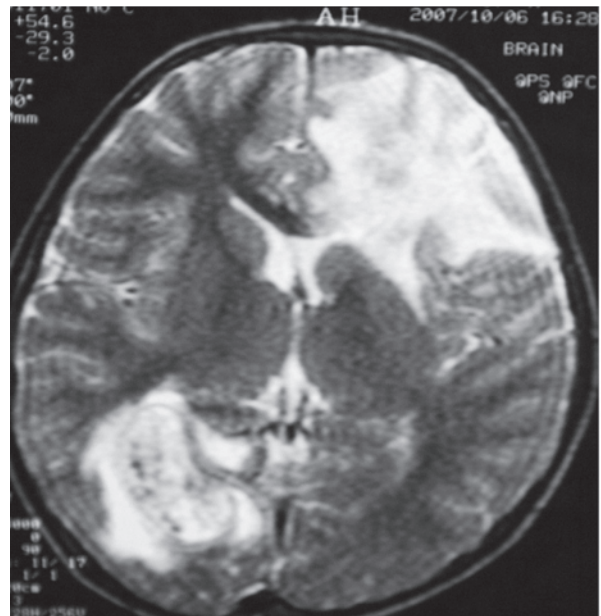
**Fig 1:** Unenhanced brain CT scan reveals hypodense lesion in left frontal lobe with mild mass effect and edema



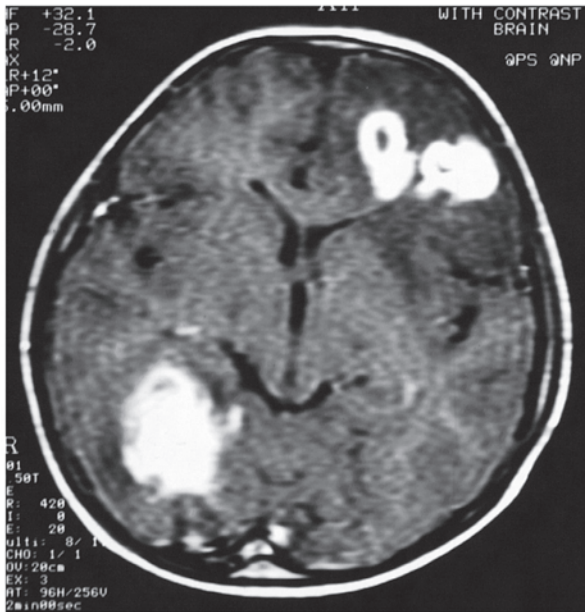**Fig 3:** Contrast enhanced CT scan at a level upper than Fig -2 reveals bizarre inhomogeneous with some ring –like enhancement in right side lesion . Note to peripheral edema around lesions .



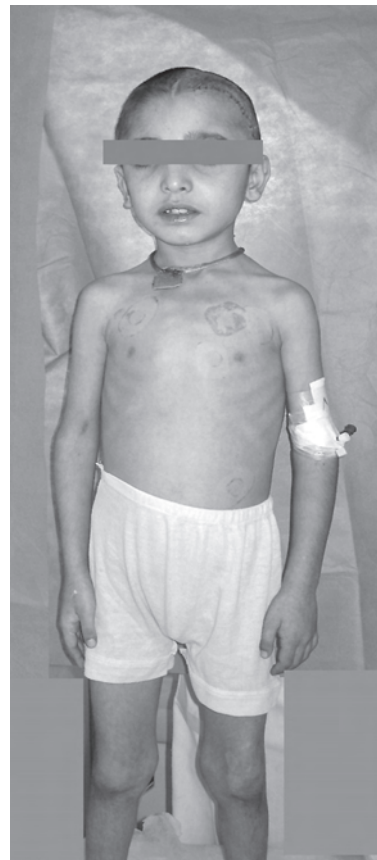**Fig 2:** Contrast enhanced CT scan reveals ring – like rim enhancement in frontal lesion and dense enhancement in right parietooccipital lesion.



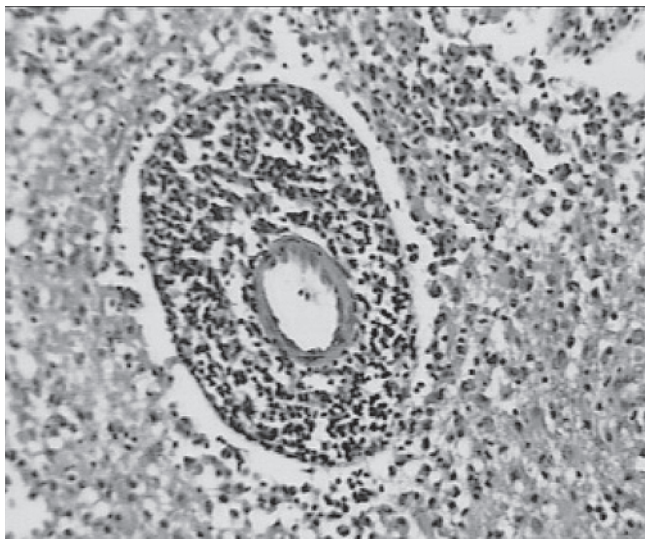
**Fig 4:** Axial T2 weighted image reveals hyperintense lesions in a same locations as seen in Fig – 2 . note to right side lesion, central hyperintensity with peripheral hypointense rim is suggestive of necrosis.



**Fig 5:** Axial T1 weighted image after contrast injection reveals thickened ring-enhancement in frontal lesion.



**Fig 7:** Our patient , 9 year old boy with PCNSL



**Fig 6:** Pathologic feature , atypical lymphoid cells with a predominantly vasocentric growth pattern .

## References

1. Cecchi pc, Billio A, colombetti V, Rizzo P, Ricci UM, Schwarz A. Primary high-grade B-cell lymphoma of the choroid plexus. *Clin Neurol Neurosurg* . 2008 Jan;110(1):75-9. Epub 2007 Oct 24.
2. Schiozawa Y, Kiyokawa N, Fujimura J, Suzuki K, Yarita Y, Fujimoto J, et al. Primary malignant lymphoma of the central nervous system in an immuneocompetent child: a case report. *J pediatri Hematol oncol* 2005 Oct; 27 (10):561-4.
3. Nimish A, Moile MD, Lauren E, Abrey MD. Primary central nervous system lymphoma. *Neurologic Clinics* 2007; 25:1193-1207.
4. Fabio M, Iwamoto MD, Lisa M, De Angelis MD. An update on Primary central nervous system lymphoma. *Hematol Oncol clin N Am* 2006; 20:1267-1285 .
5. April Fitzsimmons MD, Kristen Upchurch MD, Tracy Batchelor MD. Clinical Features and Diagnosis of Primary central nervous system lymphoma. *Hematol Oncol clin N Am* 2005; 19:689-703.
6. Soon Thye Lim, Alexandra M. Levine Hematologic Aspects of Human Immunodeficiency Syndrome. In: Marshall A. Lightman, Ernest Beutler, Thomas J. Kipps, Uri Seligsohn, Kenneth Kaushansky, Josef T. Prchal, Williams hematology. Primary central nervous system lymphoma, 7th ed. 2006 .P.1121 -1122.
7. Scrigni A, Nastri M, Rodriguez de Schiavi s, Czorny L, Felice M, Manrese B. Leptomeningeal lymphoma in a child with acquired immune deficiency syndrome . *Neuropediatrics* 2006 Jun; 37(3):121-5.
8. Karikari IO , Thomas KK , Lagoo A , Cummings TJ , George TM . Primary cerebral ALK -1- Positive anaplastic large cell lymphoma in a child. *Pediatri Neurosurg* 2007;43 (6):516-21.
9. Doolittle ND , Abrey LE , Shenkier TN , Sigegal T, Bromberg JE , Neawelt EA ,et al. Brain parenchyma involvement as isolated central nervous system relapse of systemic non-Hodgkin lymphoma: an International Primary CNS Lymphoma Collaborative Group report *Blood* 2008 February; 111(3):1085-1093.
10. Medina- Sanson A, Chico-Ponce de Leon F , Cabrera-Munoz Mde L ,Gallegos- Castorena S , Caltenco-Serrano R , Barragan- Perez E . Primary central nervous system non -hodgkin lymphoma in childhood presenting as bilateral optic neuritis. *Childs Nerv Syst* 2006 Oct; 22(10):1364-8.
11. Kimberly Cantrell, Gayle G .ClutterFaye Floyd, Michael Lanzilotta , Frances Michaud . Data collection of primary central nervous system tumors. National program of cancer registries training materials. CDC cancer 2004; 30- 31
12. A James Barkovich. *Pediatric Nneuroimaging* . 2nd ed . Raven Press:New York;2000.P. 541- 542.
13. Johnson BA, Fram EK, Johnson PC, Jacobowitz R. The variable MR appearance of primary lymphoma of the central nervous system: comparison with histopathologic features. *AJNR* 1997;18:563 -572.
14. Lanfermann H, Heindel W, Schaper J, Schroder R, Hansmann ML, Lehrke R, et al. CT and MR imaging in primary cerebral non-Hodgkin's lymphoma. *Acta Radiol* 1997;38:259-267.
15. Roman-Goldstein SM, Goldman DL, Howieson J, Belkin R, Neuwelt EA. MR of primary CNS lymphoma in immunologically normal patients. *AJNR* 1992;13:1207-1213.
16. BA Johnson, EK Fram, PC Johnson and R Jacobowitz, The variable MR appearance of primary lymphoma of the central nervous system: comparison with histopathologic features. *American Journal of Neuroradiology* 1997; 18(3):563-572.
17. Ruiz A, Post MJD, Bundschu C, Ganz WI, Georgiou M. Primary central nervous system lymphoma in patients with AIDS. *Neuroimaging Clin N Am* 1997;7:281-296.
18. Dina TS. Primary central nervous system lymphoma versus toxoplasmosis in AIDS. *Radiology* 1991;179:823 -828.
19. Namik Erdag, Rajeev M. Bhorade, Ronald A. Alberico, Naveed Yousuf, Mahesh R. Patel. Primary Lymphoma of the Central Nervous System Typical and Atypical CT and MR Imaging Appearances. *AJR* 2001; 176:1319-1326.