



Scheimpflug Imaging of Late-onset Capsular Bag Distention Syndrome Treated with Nd: YAG Laser: A Case Report

**Andreas Katsimpris^{a,b*}, Maria Moleron^b,
Aristotelis Karamaounas^a and Stylianos Kandarakis^a**

^a *First Ophthalmology Department, "G. Gennimatas" Hospital, National and Kapodistrian University of Athens, Athens, Greece.*

^b *Department of Ophthalmology, Aberdeen Royal Infirmary, Aberdeen, AB25 2ZN, UK.*

Authors' contributions

This work was carried out in collaboration among all authors. Authors AK and SK contributed to the conceptualization of the manuscript. All authors contributed to writing, review and editing of the manuscript. Authors AK and SK contributed equally to the work and should be considered co-first authors. All authors read and approved the final manuscript.

Article Information

DOI: 10.9734/IJMPCR/2023/v16i1323

Open Peer Review History:

This journal follows the Advanced Open Peer Review policy. Identity of the Reviewers, Editor(s) and additional Reviewers, peer review comments, different versions of the manuscript, comments of the editors, etc are available here: <https://www.sdiarticle5.com/review-history/95567>

Case Report

Received: 18/11/2022

Accepted: 25/01/2023

Published: 26/01/2023

ABSTRACT

Aims: To report a case of very late-onset capsular bag distention syndrome (CBDS) 8 years after uncomplicated cataract surgery treated with Neodymium: Yag (Nd: Yag) laser posterior capsulotomy.

Presentation of the Case: A 76-year-old female patient without any systemic or ocular disorders, presented with progressive blurry vision in her right eye (RE) over the last 1 year. Best-corrected visual acuity (BCVA) was 6/9 in the right eye and 6/6 in the left eye. Manifest refraction revealed a

*Corresponding author: E-mail: katsimprisandreas@hotmail.com, a.katsimpris@gna-gennimatas.gr;

0.5 diopters myopic shift in her RE compared to her last ocular examination 2 years ago. Scheimpflug photography and slit-lamp examination were utilized to make the diagnosis of CBDS, which was successfully treated with Nd: Yag laser posterior capsulotomy. At day 1 post-capsulotomy the BCVA of her RE improved to 6/6 with a 0.5 diopters hyperopic shift which was consistent with a 0.13 mm post-capsulotomy increase in the anterior chamber depth, as documented by the Scheimpflug images.

Discussion and Conclusion: Late-onset CBDS can manifest after a considerable time period following cataract surgery and Scheimpflug imaging can be a useful aid for a precise diagnosis and documentation of the treatment.

Keywords: Capsular bag distention syndrome; neodymium: Yag laser; posterior capsulotomy; Scheimpflug imaging.

1. INTRODUCTION

Capsular bag distention syndrome (CBDS) is a fairly rare postoperative complication of cataract surgery with posterior chamber in-the-bag intraocular lens implantation (IOL), first described almost 30 years ago [1]. CBDS is characterized by the entrapment of fluid between the IOL and the posterior capsule, which can potentially cause forward displacement of the IOL and can result in a broad spectrum of clinical outcomes ranging from myopic shift to increased intraocular pressure (IOP) and decrease in visual acuity [2].

Depending on the time of CBDS onset, it can be classified into intraoperative, early postoperative and late postoperative [3] with the latter type also known as lactecrumenasia. Late postoperative CBDS can occur months to years after cataract surgery, and it is the most uncommon type of CBDS. In this type of CBDS, the accumulated liquified material has milky-white turbid appearance, which results in decrease of the patients' visual acuity and, thus, it should be evacuated [2]. Several imaging techniques have been deployed to properly diagnose and document the progression of CBDS [4,5], including optical-coherence tomography, ultrasound biomicroscopy and Scheimpflug photography. The latter is considered as one of the best tools to adequately provide information regarding the success of the treatment as well as presence of concomitant entities like posterior capsule opacifications. In this report, we present a case of late-onset CBDS 8 years after uncomplicated cataract surgery treated with Neodymium: Yag (Nd:Yag) laser posterior capsulotomy.

2. PRESENTATION OF CASE

A 76-year-old female patient presented to the outpatient clinic of our tertiary ophthalmology

department (First Department of Ophthalmology, General Hospital "G. Gennimatas", Athens, Greece), for routine examination. She complained for progressive blurry vision in her right eye (RE) over the last 1 year. She had undergone uneventful bilateral cataract surgery 8 years ago with implantation of 1-piece acrylic posterior chamber IOLs of +23.5 and +24.0 diopters in the RE and left eye (LE), respectively (enVista® MX60; Bausch and Lomb Incorporated, Rochester, NY, USA). Her past medical and family history was unremarkable. At her last ophthalmological examination 2 years ago her best-corrected visual acuity (BCVA) was 6/6 in both eyes, with a manifest refraction of -0.25 -1.25 x 140 and -0.25 -0.50 x 180 in the RE and LE, respectively.

Upon examination, her visual acuity was 6/6 in the LE with the same manifest refraction as 2 years ago. BCVA of the RE was 6/9 with a manifest refraction of -0.75 -1.25 x 140, indicating a myopic shift of 0.5 diopters compared to her last examination. Intraocular pressure in the RE and LE, was 17 and 13 mmHg, respectively. The slit-lamp examination of the RE revealed distention of the capsular bag with accumulation of turbid fluid between the IOL and the posterior capsule (Fig.1A). Gonioscopy revealed Scheie's angle opening grade 4 and 2 in all quadrants, in the RE and LE, respectively. No evidence of inflammation was present in the anterior chamber and vitreous of RE and the rest of the ocular examination for both eyes was unremarkable. Scheimpflug imaging (Pentacam HR, Oculus, Wetzlar, Germany) of the RE was done to precisely document the presence of the fluid and the success of the treatment (Fig.2). Corneal tomography showed the exact extend of capsular distention and anterior chamber depth (Fig. 2A) as well as the turbidity of the fluid from the densitometric analysis. The diagnosis of late-onset CBDS was made and we decided to

proceed with Nd:Yag laser posterior capsulotomy to release the sequestered fluid. The patient agreed with our treatment plan and written informed consent was obtained from her.

Topical 2.5% phenylephrine hydrochloride and 1% tropicamide were instilled in the RE to achieve adequate pupil dilation. After 20 minutes topical 0.5% proparacaine hydrochloride was instilled to achieve topical anesthesia and a 10 mm Ocular Abraham Capsulotomy lens (Ocular Instruments, WA, US) coupled with 0.2% carbomer gel was used to improve our visualization of the capsule and ocular stability. We used the single pulse mode of the Nd:YAG laser (VISULAS YAG III, Carl Zeiss Meditec, Jena, Germany) and the capsulotomy was created in a spiraling circular pattern. The entrapped turbid fluid was released and drained into the vitreous, and the capsular block was relieved as it can be seen in the slit-lamp photographs (Fig. 1) and the Scheimpflug images (Fig. 2). A post-capsulotomy increase of 0.13 mm in the anterior chamber depth of RE was documented in Scheimpflug images (Fig. 2).

In order to prevent any transient IOP spikes, the patient received one drop of brimonidine tartrate 0.2% (Alphagan; AbbVie, Greece) immediately after the procedure in the RE and commenced on 0.1% dexamethasone drops (Maxidex; Novartis Hellas, Greece) four times a day, as well as, dorzolamide 2%/timolole 0.5% (Cosopt; Vianex, Greece) 2 times a day, for 3 days. The patient was examined at day 1 after the capsulotomy and her BCVA of the RE was 6/6 with a manifest refraction of -0.25 -1.25 x 140, indicating a hyperopic shift of 0.5 diopters which was consistent with the post-capsulotomy increase in the anterior chamber depth of the LE (0.13 mm). No retinal abnormalities were found in dilated funduscopy examination.

3. DISCUSSION

In this report we describe a case of late-onset CBDS documented with Scheimpflug imaging and treated with Nd:Yag laser posterior capsulotomy. The postulated pathophysiological mechanisms of CBDS differ according to the type of CBDS. Intraoperative CBDS occurs due to entrapment of balance salt solution in the retrolenticular space during the hydrodissection stage, more commonly in white or posterior polar

cataracts with small capsulorrhexis, because of the high irrigation pressures required in these types of procedures [2]. Retained intracapsular viscoelastic or lens material are the most prevalent causes of early-onset CBDS [6,7], which occurs during the first two weeks following cataract surgery. The entrapped material in this type of CBDS may cause an osmotic gradient across the capsule, resulting in intracapsular aqueous humor accumulation [7]. As a result of the capsular distention, IOL is displaced forward and postoperative myopic shift or/and high IOP can occur.

In late-onset CBDS, the accumulated turbid fluid has been postulated to be produced by retained metaplastic epithelial cells of the lens, which they also fill the space between the anterior capsule and the IOL, causing the capsular opening to get sealed [6]. This turbid fluid has been shown to have high levels of alpha-crystallin and low concentrations of albumin, supporting the postulated hypothesis that it is derived from the metaplastic epithelial cells [2]. Late-onset CBDS typically manifests around 4 years post-operatively and the findings of myopic shift and high IOP are less common compared to early-onset CBDS [2]. Furthermore, longer axial length (≥ 25 mm), small continuous curvilinear capsulorrhexis and IOL with large sizes have been identified as potential risk factors for CBDS [6]. Our case was remarkable in that the symptoms did not appear until 8 years following a routine cataract surgical procedure and also the RE axial length of the patient was normal. Moreover, our patient experienced mild symptoms of blurry vision, which disappeared following the capsulotomy, in contrast to the majority of the documented literature, where the visual acuity was substantially diminished.

The majority of the time, the diagnosis of late-onset CBDS may be made based only on the findings of a clinical examination. Several factors, like the presence of turbid fluid between the IOL and the posterior capsule and post-operative progressive myopic shift, may aid in making a diagnosis of late-onset CBS. Imaging modalities such as anterior segment ultrasound biomicroscopy [8], optical coherence tomography [2], and Scheimpflug photography [9] are all useful diagnostic tools that can assist ophthalmologists in making an accurate diagnosis and documenting this entity.

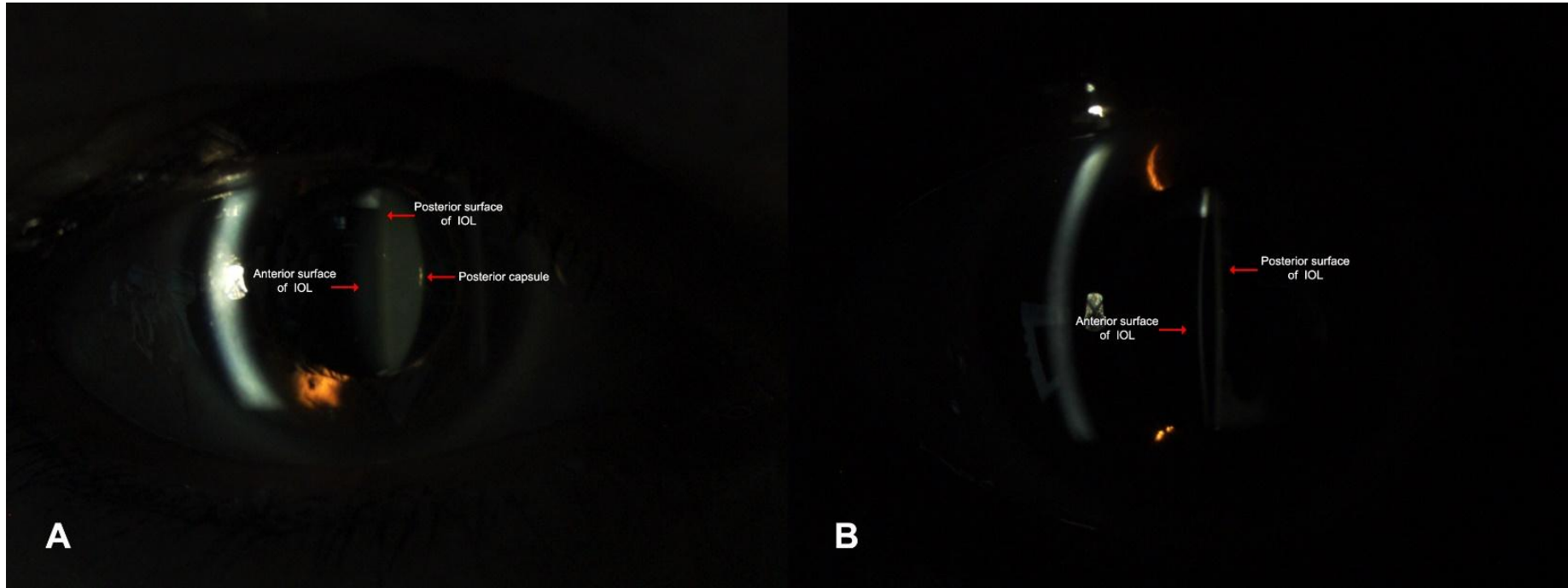


Fig. 1. A) Slit-lamp photography of the right eye showing accumulation of yellow material between the intraocular lens (IOL) and Posterior Capsule (PC). B) Slit-lamp photography of the same eye after evacuation of the fluid with Nd: YAG laser posterior capsulotomy




Fig. 2. A) Scheimpflug image of the right eye showing distended capsular bag with sequestration of dense material between the intraocular lens (IOL) and Posterior Capsule (PC). B) Scheimpflug image of the same eye after evacuation of the fluid with Nd:YAG posterior capsulotomy

4. CONCLUSION

In conclusion, late-onset CBDS can appear after a long period of time following cataract surgery. In most of these cases, Nd:YAG laser capsulotomy remains the standard method of therapy. Although several imaging techniques exist that can facilitate the diagnosis of CBDS, Scheimpflug imaging has been found in many cases in the literature to be one of the best ways to document the success of CBDS treatment, as well as, to identify changes in the anterior chamber depth pre- and post-capsulotomy.

CONSENT

All authors declare that written informed consent was obtained from the patient for publication of this case report and accompanying images.

ETHICAL APPROVAL

As per international standard or university standard written ethical approval has been collected and preserved by the authors.

COMPETING INTERESTS

Authors have declared that no competing interests exist.

REFERENCES

1. Davison JA. Capsular bag distension after endophacoemulsification and posterior

- chamber intraocular lens implantation. J Cataract Refract Surg. 1990;16(1):99-108.
2. Vélez M, Velásquez LF, Rojas S, Montoya L, Zuluaga K, Balparda K. Capsular block syndrome: A case report and literature review. Clin Ophthalmol. 2014;8:1507-13.
 3. Galvin JC, Berdoukas P, Fung AT. Two cases of very late-onset capsular bag distension syndrome. American Journal of Ophthalmology Case Reports. 2018;10:268-70.
 4. Kanclerz P, Wang X. Postoperative capsular bag distension syndrome - risk factors and treatment. Semin Ophthalmol. 2019;34(6):409-19.
 5. Almousa KS, Refka MN. Late-onset capsular bag distention syndrome resistant to laser treatment: A case report. J Surg Case Rep. 2021;2021(7):rjab278.
 6. Kim HK, Shin JP. Capsular block syndrome after cataract surgery: Clinical analysis and classification. J Cataract Refract Surg. 2008;34(3):357-63.
 7. Sugiura T, Miyauchi S, Eguchi S, Obata H, Nanba H, Fujino Y, et al. Analysis of liquid accumulated in the distended capsular bag in early postoperative capsular block syndrome. J Cataract Refract Surg. 2000;26(3):420-5.
 8. Almousa KS, Refka MN. Late-onset capsular bag distention syndrome resistant to laser treatment: A case report. Journal of Surgical Case Reports. 2021;2021(7).
 9. Zhu X, Lu Y. Detection and influencing factors of capsular bag distention syndrome after cataract surgery using the pentacam scheimpflug system. Am J Ophthalmol. 2013;156(6):1134-40.e4.

© 2023 Katsimpris et al.; This is an Open Access article distributed under the terms of the Creative Commons Attribution License (<http://creativecommons.org/licenses/by/4.0>), which permits unrestricted use, distribution, and reproduction in any medium, provided the original work is properly cited.

Peer-review history:
The peer review history for this paper can be accessed here:
<https://www.sdiarticle5.com/review-history/95567>