



Pediatric Liver Transplantation: Methods and Results

Omar Elsaka ^{a*}, Moneer Ayman Nouridean ^a, Mohamed Adel Gamil ^a,
Mostafa Tarek Ghazali ^a, Ashraf Hamada Abd Al-Razik ^a and Dalia Hisham ^a

^a Department of Pediatrics, Mansoura University, Faculty of Medicine, Mansoura, Manchester Medical Program (MMMP), Mansoura, Egypt.

Authors' contributions

This work was carried out in collaboration among all authors. All authors read and approved the final manuscript.

Article Information

Editor(s):

- (1) Dr. José Francisco de Sales Chagas, São Leopoldo Mandic Medical School, Brazil.
(2) Dr. Ramesh Gurunathan, Sunway Medical Center, Malaysia.

Reviewers:

- (1) Serdar OLT, Adiyaman University, Turkey.
(2) Krishna Kumar G, India.
(3) Kalinca da Silva Oliveira, Federal University of Health Sciences of Porto Alegre (UFCSPA), Brazil.
Complete Peer review History, details of the editor(s), Reviewers and additional Reviewers are available here:
<https://www.sdiarticle5.com/review-history/80066>

Review Article

Received 22 October 2021
Accepted 27 December 2021
Published 30 December 2021

ABSTRACT

Background: In recent years, liver transplants for children have become increasingly effective and low mortality rates. advances in science, surgery and neurosurgery, organ access, immunization, diagnosis and treatment of modern submissive head have resulted in improved implants and survival of the victims. Use of liver transplants and live donors have donated large organs to pediatric patients. New immune structures, as well as induction therapy, significantly affect graft and patient survival. Future developments of modern children's liver transplants will focus on long-term adherence, preventing headaches associated with the immune system, and, where possible, the promotion of daily development. This study describes recent developments in liver transplantation in children. Graft survival rates in patients aged 10 and older were 75%, 61%, 74% and 60%, respectively.

Conclusion: that the survival rate for children under one year of age or weighing less than 10 kg is usually between 65% and 80%, which was better compared 50-60%.

Keywords: Pediatric liver transplantation; hepatoblastoma; pediatric liver tumors; hepatocellular carcinoma.

1. INTRODUCTION

Liver transplants are very popular in the treatment of children with chronic liver disease and allow them to live longer and healthier lives. Orthopedic Surgery With the great difficulty of making full use of implants and the need for better surgical procedures, all children who need help, even the youngest, have the opportunity to have a transplant today, without dying on the list. Harvested liver transplants and organ transplants have had the effect of changing the status quo in the 1980s and 1990s [1].

In children, death on the waiting list is better than in older patients. A few years ago, liver transplants became the norm in child care as a means of preventing liver disease, but in recent times the main interest has been long-term. On the contrary, it aims to prevent headaches associated with physical stress and to sell as common an increase as possible. The history of pediatric liver transplantation has shown that easy eradication depends on strong and complete collaboration between pediatricians, pediatric hepatologists, surgeons, nurses, prosthetic coordinators, psychologists and social workers. Each participant is challenged to treat pediatric patients with their most serious medical problems [2].

2. INDICATIONS FOR LIVER TRANSPLANTATION

The main indications for liver transplantation in children are as follows (Fig. 1) (1) Extrahepatic cholestasis: biliary atresia. (2) Intrahepatic cholestasis: sclerosing cholangitis; Alagille syndrome; syndromic deficiency of intrahepatic bile ducts; and modern intrahepatic family

cholestasis. (3) metabolic disorders: Wilson's illness; α 1-antitrypsin deficiency; Crigler-Najjar syndrome; birth defects within the bile acids trade; tyrosinemia; violation of the urea cycle; organic acid; acid lipase dysfunction; type of oxaluria; and problems with carbohydrate metabolism. (4) Severe liver failure. (5) Others: the first number of liver tumors and cystic fibrosis [3].

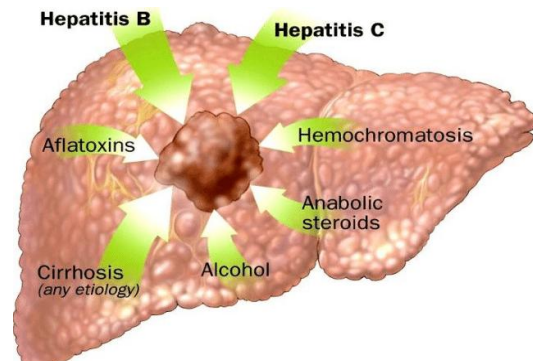


Fig. 1. Hepatocellular carcinoma causes [3]

3. CONTRAINDICATIONS TO LIVER TRANSPLANTATION

The modern contraindication to liver transplantation in children is: (1) A non-preventable hepatic invasion. (2) Failure of the limb of the corresponding position which cannot be fixed by a combined replacement. (3) Uncontrollable sepsis. (4) Severe irreversible emotional damage. For adults, access to a liver transplant waiting list is only available for those with liver tumors, but for children, this method is very kind and the symptoms need to be discussed on my part. In all cases by a pediatric oncologist (Fig. 2) [4].

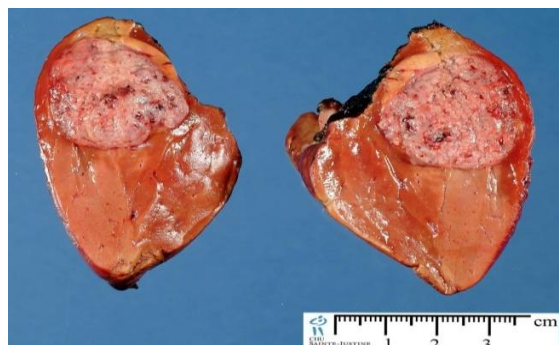

Fig. 2. Hepatoblastoma [4]

4. EVALUATION OF THE TRANSPLANT CANDIDATE

The primary purpose of the screening process is to identify applicants for the appropriate transplant applications and to establish a pre-transplant system. The following steps are often considered: (1) Confirm the index of the replacement; (2) Grant weight gain; (3) Do not forget the treatments that offer the opportunity for transplantation; (4) Do not incorporate conflict reorganization; (5) Selecting organic pollutants and comparing the child's body image; (6) Remove any cardiac damage that may need to be repaired before the implant; (7) Establish a pre-implant healing plan: vaccination whenever possible, dietary guidelines for growth, dental care, prevention or treatment of drug-induced side effects (and osteopenia secondary to extended steroid use); (8) Tell the person deciding or affected, if possible, the method of the implantation and the post-implantation length to encourage them to immediately accept and deal with all possible problems and procedural problems. (9) Examine social and organizational issues [5].

5. METHODS

5.1 Living-Related Liver Transplant

Sections 2 and 3 were collected from a live donor (mother) and the first description of the transplant system for a child with bile atresia dates back to 1988. Life-related liver transplants began to provide examples of the larger species of children. Many resources around the sector, as well as liver transplants in countries where

organ transplants were banned a few years ago (Fig. 3) [6].

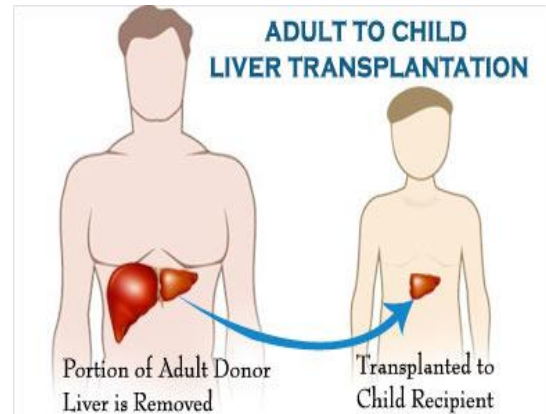


Fig. 3. Living-related liver transplantation [7]

5.2 Whole-Liver Transplant

The whole liver procedure from a pediatric donor is performed in the same way as an adult, using a method that combines the original collection method described by Starzl et al [6] and the newly established rapid bath [7] Is. Complete liver transplants for children can be done in two different ways. The traditional method under the vena cava restoration and the piggyback connection method of retaining the native vena cava [8]. The doctors often use the traditional method in most cases of liver transplants. The endocrine system is rarely used in pediatric liver transplants, as patients generally tolerate better dosage, if the exchange is appropriate. The technology to be followed is almost identical to that used by recipients (Fig. 4) [8].

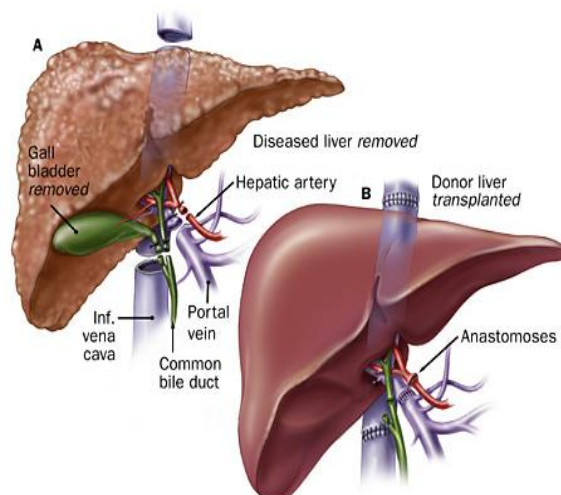


Fig. 4. whole liver transplantation [9]

5.3 Reduced-Size Liver Transplant

The procedure was first described using bismuth and involves the harvesting of the whole liver from an adult donor whose size has been reduced inside the back table. In the official definition, a proper hepatoctomy is performed on the back desk. The right lobe of the liver was removed and the left side of the liver was inserted into the child by vena cava (parts cinema lever 1 to 4). This comprehensive reduction technique, rarely used today, allows surgeons to eliminate donor and recipient size differences in up to 4-5 cases (Fig. 5) [10].

Split-liver Transplantation: As first noted by Pichlmire, some liver transplants completely free the liver from the cadaveric donor and separate us in areas near the circular lines, leaving the vascular structure of each part of the parenchyma complete. It includes production. As a result, partial organs are found in the same liver: the left ventricle (Fig. 6) which can be transplanted directly into the newborn and the enlarged natural liver (stages 1 and 4-8) adults can be transferred to the baby. This process, with a very long ischemic time, was very common and ineffective with the first number of

inactivity and technical problems at the beginning of use (Fig. 7) [12].

Donor Selection: The following factors should be considered when evaluating a preferred patient provider: Version size: It is important to adhere to the selection of graffiti with a sufficient parenchymal weight. The small liver weight necessary for recovery is not really established, and its calculation should take into account donor damage or compensation, as well as temporary hepatocytes deficiency in care damage, severe rejection, or technical problems. Several formulas have been proposed to measure daily liver function in adults and children [15].

Donor characteristics: Donor organ function is distinguished by comparing medical records with biological chemical tests. The conditions for selecting donors around the world are usually the purchase of an explosive liver [16]: (1) 15 to 50 years; (2) Weight > forty kg; (3) no history of liver injury / disorder; (4) liver function see between 2-5 cases of normal values; (5) the daily appearance of the connection; (6) hemodynamic balance.

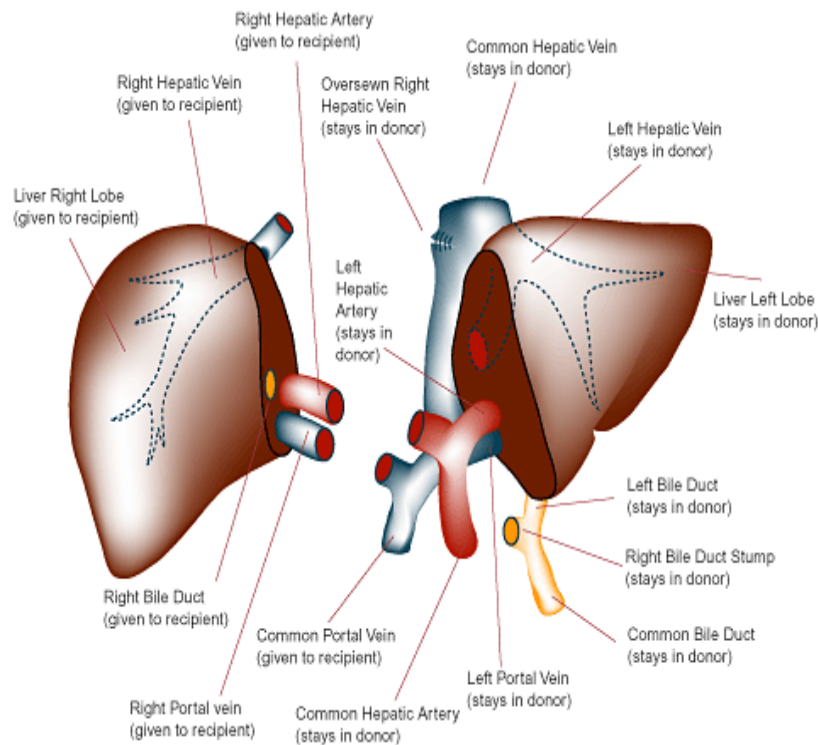


Fig. 5. reduced size liver transplantation [11]

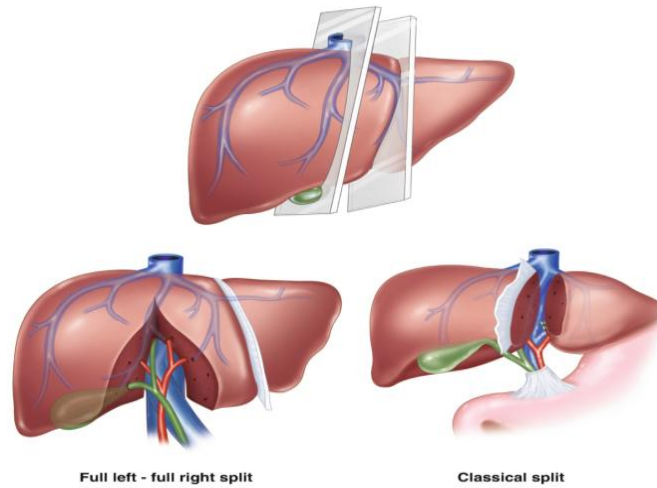


Fig. 6. Split liver transplantation [13]

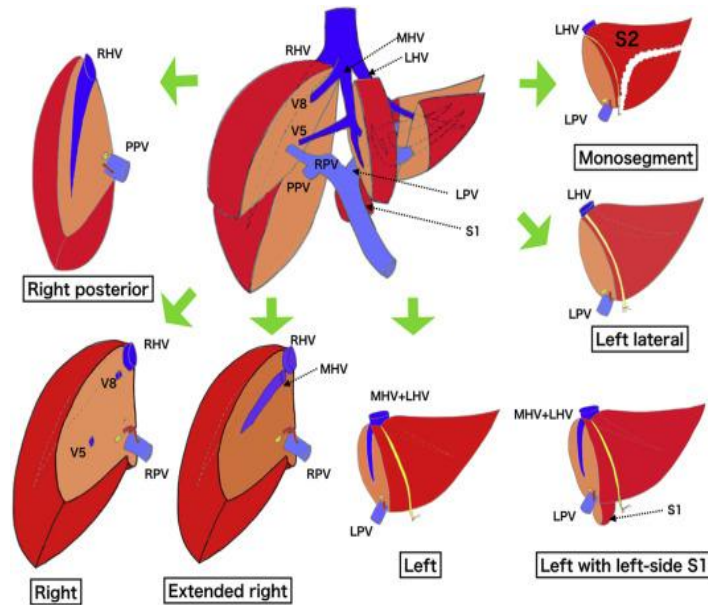


Fig. 7. Different types of liver allografts [14]

The choice of accommodation providers and the replacement of live donors, usually the evaluation and selection of the accused donors or first-degree relatives, is based on the belief that donor safety is guaranteed and features of the donor's courage are common. increase. Donors are between the ages of 18 and 55 and should be well matched to the ABO blood group (Fig. 8) [17].

Donor Operation: For left attachment, part of the liver is shaped like a falciparum ligament, consisting of stages 2 and 3, including the left ventricle, the left side of the portal vein, and the left side of the hepatic artery. Installed. Normal

hepatic artery and celiac tripod, with the right part comprising stages 1 and 4 to 8, as well as the vena cava, the right branch of the hepatic artery, and the portal artery where the mesenteric and splenic veins start there. . At the onset of fractures, the hepatogastric ligament is examined to detect the left ventricular artery from the left abdominal artery, which must be maintained. Although the vessel is not always fixed, ligament phaseing is performed. Normal hepatic artery is then identified and separated from the right and left hepatic arteries with the help of the gastroduodenal artery. The left artery is then blocked [18].

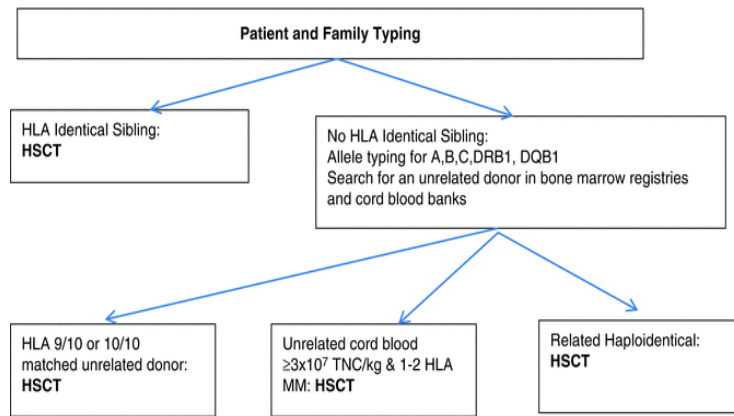


Fig. 8. Donor selection methodology [17]

If there is a branch from stage 4 hepatic artery, it needs to be identified and separated. The lower part of the circular ligament is opened by breaking a small parenchymal bridge connecting the 4th section and the left facet section of the liver. In the fourth step, a circular ligament is created, fully integrated, the venous connections are kept separate and cut. When the circular ligament is separated, an additional portion of the left branch of the portal vein appears below the left hepatic artery. This vein should be carefully dissected and circumcised [19]. Rotate the left side to the right and cut inside the venous vein to the left hepatic artery. Can be disassembled and modified [20].

The left bile duct is contained within the hepatic portal vein and no longer needs to be separated. instead, the hepatic site should be rounded and determined significantly [21]. The parenchymal part can now be formed near the falciform ligament [22]. In determining the anatomical location, it is helpful to skip a piece of cotton that surrounds the left artery in the posterior area of the liver within the ductus venosal fossa side to side to the left branch of the hepatic artery and portal artery [23].

By drawing this drawing, it is usually easier to separate the parenchyma. At this stage, the procedure remains the provider's preferred operation, including high blood pressure, brushing and binding of the aorta, filling and cooling of the abdominal cavity. The left artery becomes narrower near the artery. Care must be taken to locate the remote part of the artery. The double left vein graft greatly increases the complexity of the technology. In this case, the vessel should be removed with a venous cuff to allow for a single vascular anastomosis with the

vena cava recipient. The left part of the portal vein is small near the parenchyma. The hepatic artery itself is separated near its original site, and the hepatic artery is separated from the celiac artery, which is removed by capillary cap (Fig. 9) [24].

Recipient Operation: The recipient hepatectomy is performed as described above for complete liver transplantation using the "rotation" method [25]. The left lateral graft is significantly different from the whole graft implantation. To ensure adequate venous drainage, a careful insertion technique between the left hepatic vein of the graft and the recipient's inferior vena cava, as well as correct positioning of the graft, which is rotated 45 ° clockwise in the transverse direction, is required. Flat and slightly sideways. Frontal plane. The final role of the parenchymal cut surface, including the new hilar of the graft, is high and posterior so that the portal vein and hepatic artery are curved and longer than usual [25].

6. POSTOPERATIVE COMPLICATIONS

Primary Non-Function: In the first hours after the implantation, there may be a lack of graft recovery, lactate cycle repetition, improved prothrombin time, and partial thromboplastin time, and the affected person may not be able to wake up despite sleep apnea. This is a very complex problem due to the injection of prostaglandin E1 to prevent the effects of liver failure, inflammation of the brain (mannitol injection, hyperventilation) and the necessary means to prevent plasma injection and glucose. It is important to treat it aggressively and promptly [26].

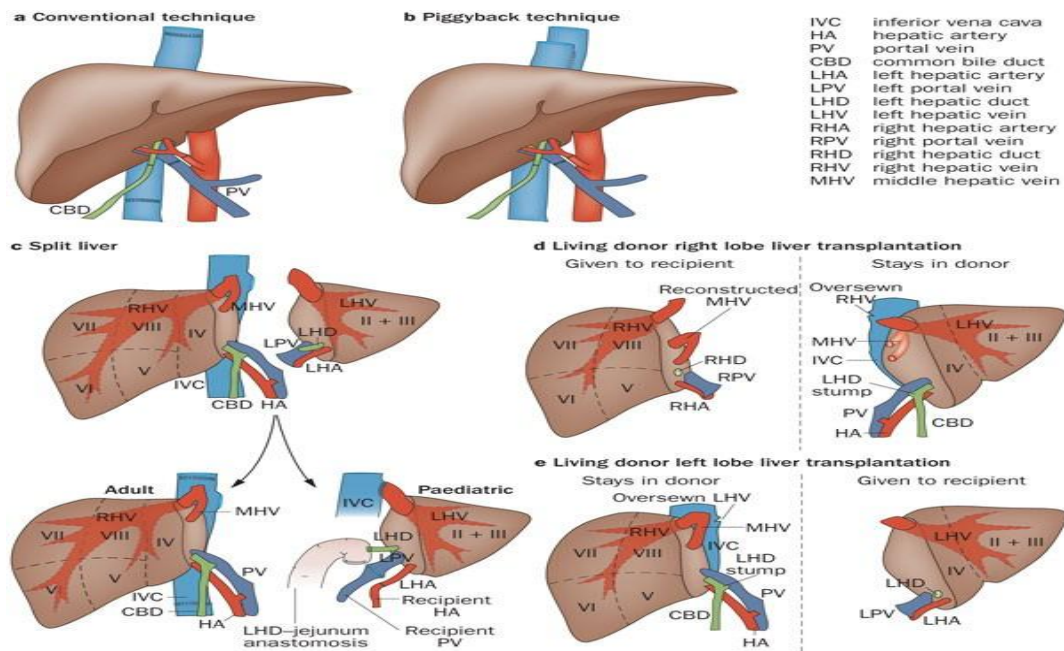


Fig. 9.Types of donor operations [24]

Hyper Acute Rejection: Approximately 20-50% of patients experience at least one episode of overdose in the first few weeks after liver transplantation. Therapeutic images of rejection include fever, high sensitivity, hypertension, leukocytosis, common eosinophilia and an increase in GT, bilirubin and transaminase (Fig. 10) [26].

Biliary Complications: Depending on the type of allograft used, approximately 10 to 30% of liver transplant recipients experience biliary head pain. The presence of gall-like fluid in the abdominal drainage prematurely after surgery clearly indicates gall loss. Ultrasound detection of intrahepatic bile duct dilatation, long-term injection of alkaline phosphatase and gamma-glutamyl (GT) and or recurrent cholangitis (Fig. 11) [27].

Vascular Complications: Anastomosis of the hepatic artery carries a high risk of thrombosis (5-18%) and, if started early, leads to necrosis of large grafts. Hepatic artery thrombosis is more common in children 3-4 times than in others, and usually occurs in the first 30 days after transplantation and in children with total liver transplantation (Fig. 12) [28].

Retransplantation: In the second view early recovery is commonly used in many high-quality diagnostic and therapeutic centers for intestinal damage due to bile, bleeding, gastrointestinal adhesions and sepsis. Young children and

infants, who are the easiest to close the first skin, need a second laparotomy to close the fascia within 5-7 days [29].

Post-Transplant Lymphoproliferative Disorders (PTLDs): PTLD is a group of conditions ranging from benign lymphoplasia to lymphoma. PTLD is the most common tumor in children after transplantation and most cases in the first two years after transplantation. The postponed type often has aggressive scientific guidance and extreme diagnoses. The development of PTLD in pediatric liver transplant patients is supported by the complexity of the immune system, their lifespan, and the lack of early detection of EBV infection in 60% -80% of patients [29].

The risk factors for developing PTLD are [30]: (1) The total immunosuppressive value is high. (2) Recipients who are unaware of EBV. (3) An active viral load.

No human immunosuppressant is immediately associated with PTLD. EBV infection is the primary pathogenesis that supports PTLD correction. Treatment of PTLD is based entirely on immune cell typing and clinical manifestations. It is necessary to withdraw immediate relief or suppression of the immune system considering the high risk of organ PTLD rejection (Fig. 13) [30].

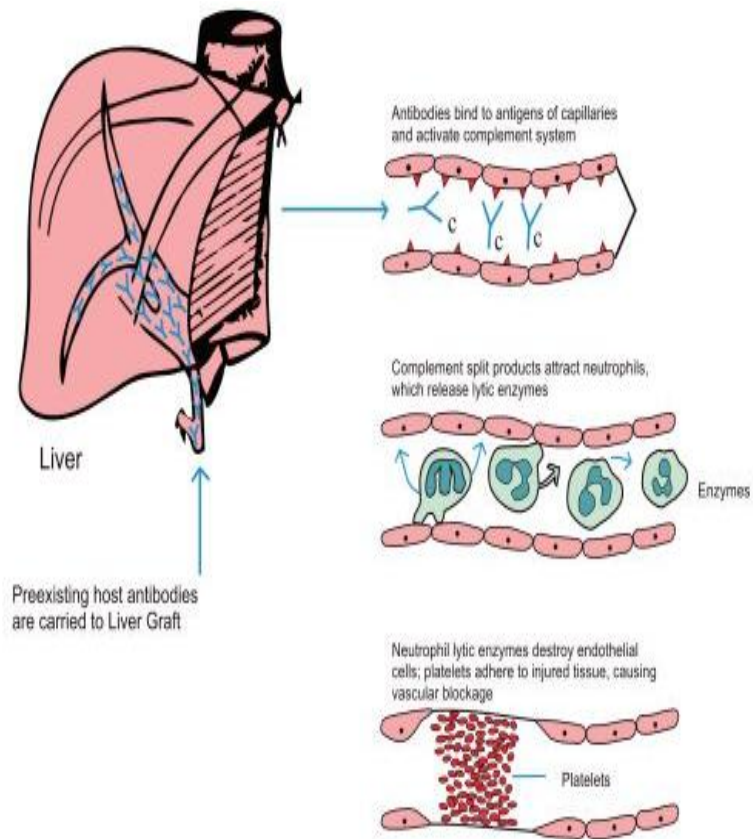


Fig. 10. Mechanism of hyper acute rejection after transplantation [27]

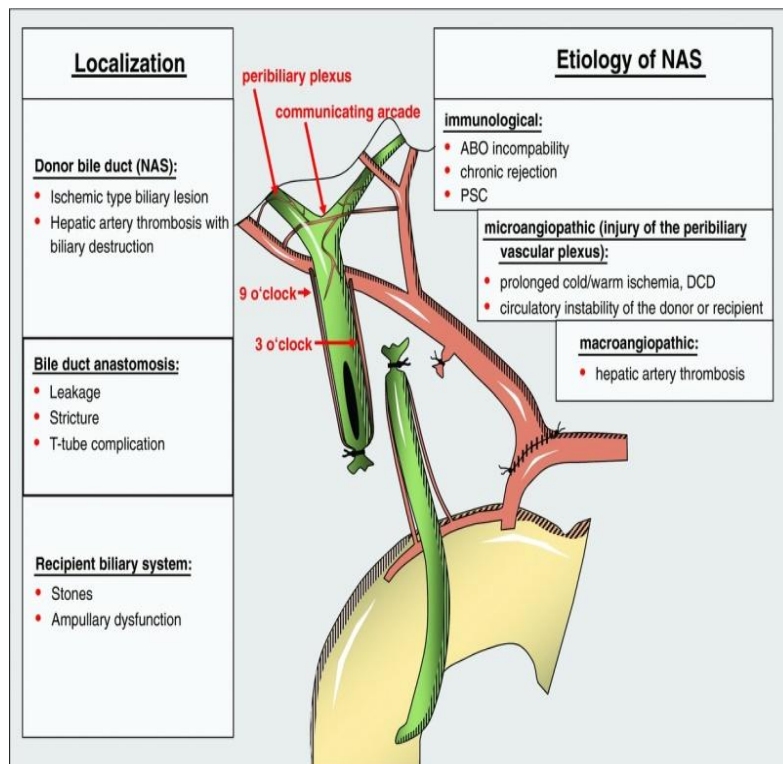


Fig. 11. Biliary complications after transplantation [27]

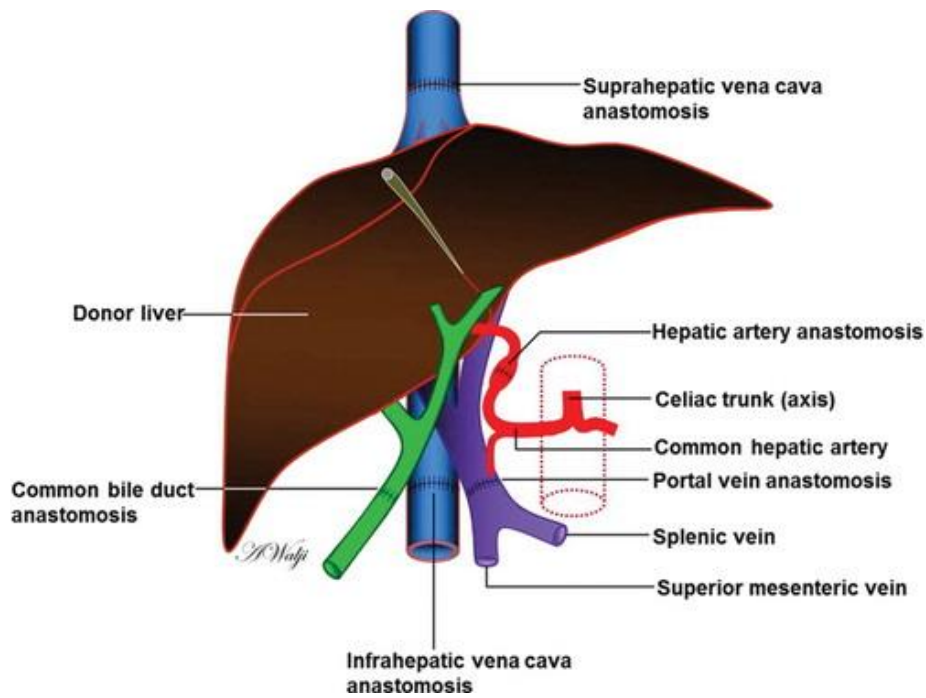


Fig. 12. Vascular thrombosis sites after transplantation [28]

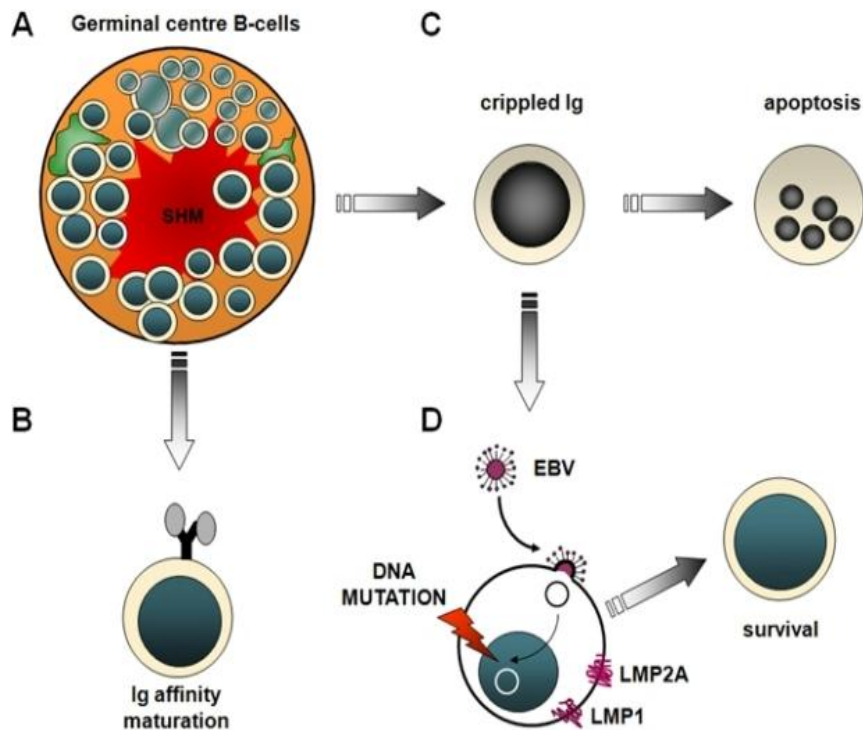


Fig. 13. Post-transplant allograft disorder (PTLDS) [30]

Late Allograft Dysfunction: Differential diagnosis may be difficult due to the many possible causes of lateograft allograft and the differing scientific, serologic, and histopathologic abilities. The recurrence of autoimmune liver

disease after implantation is less important in children than in adults. The most common infections and complications of immune systems are the most difficult diagnostic challenges (Fig. 14) [31].

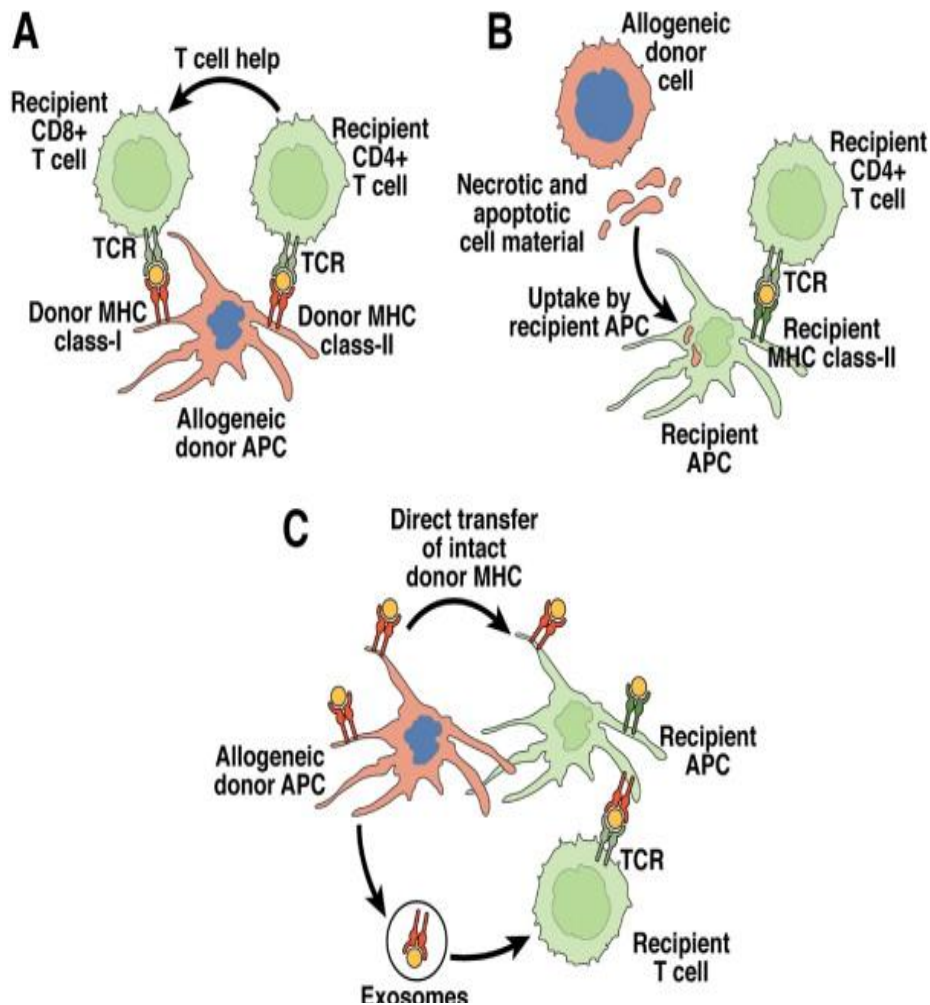


Fig. 14. Late allograft dysfunction [31]

7. MEDICATION

Corticosteroid: Corticosteroids are the main drug for controlling rejection, yet they are an important part of immunosuppressive therapy; they are effective in preventing and treating graft reactions. They act on intracellular receptors expressed in all scaffold cells (Fig. 15) [32].

Calcineurin Inhibitors: Cyclosporine and tacrolimus are classified as calcineurin inhibitors because they inhibit the T cell response and bind to an intracellular protein called immunophilin (Fig. 16) [32].

Mycophenolate Mofetil: Mofetyl mycophenolate, an active metabolism of mycophenolate E, is a selective inhibitor of the enzyme inosinic acid dehydrogenase, essential for de novo purine synthesis. Suppression of the effects of the de novo method by reducing the content of guanosine nucleotides and

stopping lymphocyte replication. This is because potential mechanisms for nucleotide production are not available (Fig. 17) [32].

8. DISCUSSION

The general effects of liver transplants are helpful. The European Liver Transplantation Registry (ELTR) examines liver transplants in Europe and represents 84% and 73% of the 5,895 transplanted children between 1988 and 2005, respectively. Implantation time for children under 2 years with 81% and 71%, respectively. Graft survival rates in patients aged 10 and older were 75%, 61%, 74% and 60% respectively. In addition, UNOS recorded a survival rate of 9,064 rehabilitated pediatric patients between 1997 and 2004. One, three and five years of affected individuals and living standards depending on the age of the recipient at the time of implant [33].

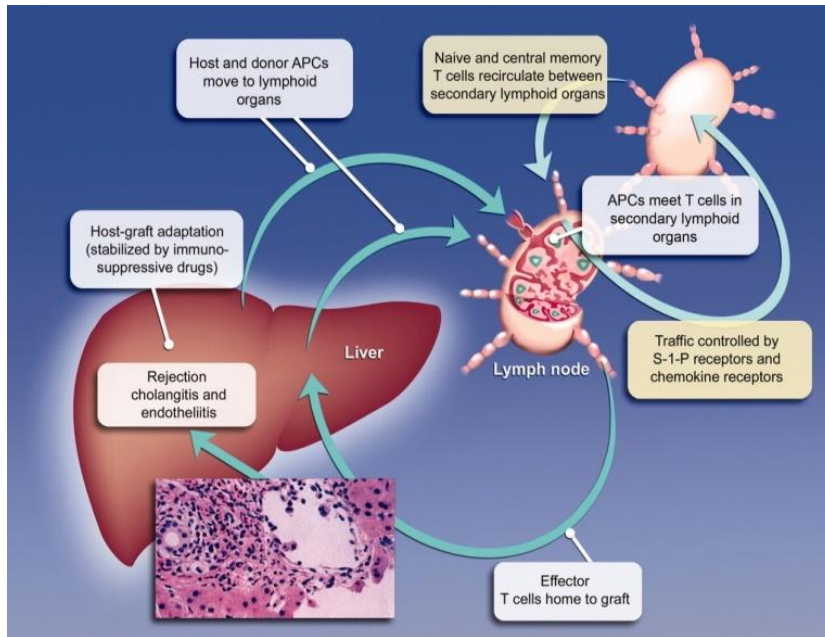


Fig. 15. Corticosteroid immunosuppressive role [32]

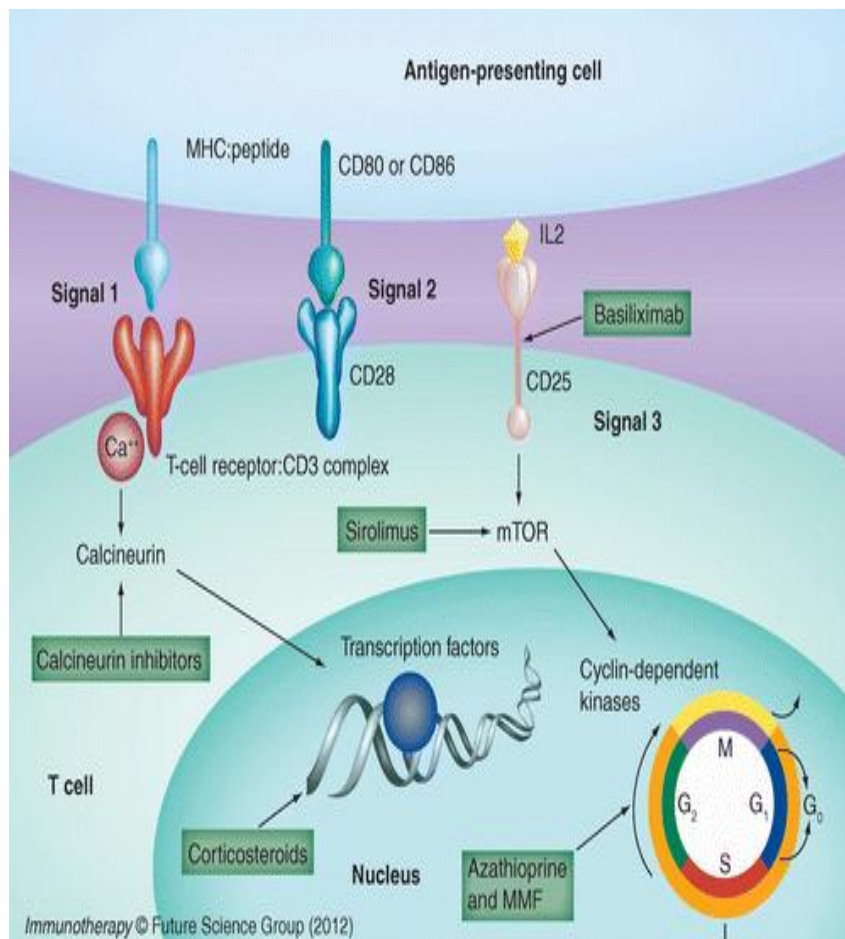


Fig. 16. Calcineurin inhibitors mechanism of action [32]

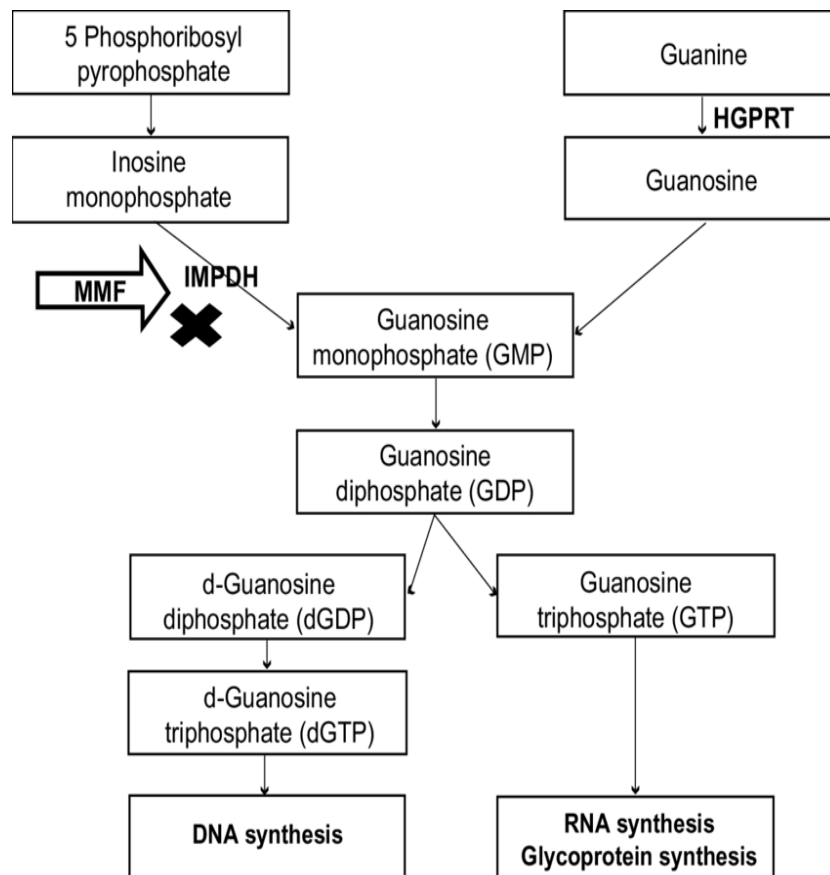


Fig. 17. Mycophenolate mofetil mechanism of action [32]

Pediatric liver transplants (prescribed) represent 1611 patients at the enrollment site, survival of normal patients at 1-12 months and allogeneic implants up to 88% and 82% respectively, 83% and 74% after four years . Certain factors affecting the survival of premature implants include age, diagnosis, severity of the disease, and possible type [33].

Assessing the severity of the disease, especially the burden of its progression, can be difficult. Nearly one in six patients undergoing a transplant may be considered at least not considered eligible for immediate transplant at least immediately. In most cases, these facts could not be collected from data submitted prior to testing. Most of these victims were treated “very” and had few, if any, symptoms. Given the dramatic increase in survival of 3 years, it seemed appropriate in our view to stop the transplant until the patient is clinically in the pot [33].

It has resulted in the refusal of 4 patients for transplantation and specialized treatment of the other two due to the presence of non-liver

disease. Aneurysm shunts that occur in chronic liver disease are said to be closed after 11'12 implants. 13 The experience of one patient with hepatogenic cyanosis had a negative effect, leading to the rejection of every patient with a deep cyanotic. An additional patient with liver failure due to neonatal hepatitis did not experience kidney failure, hydronephrosis, and kidney failure. He was rejected and eventually died. The current benefits of organ transplants allow the same patients to have their liver and kidneys transplanted at the same time. A non-clinical laparotomy was found in two different patients with additional 1T metastasis from their hepatoma. Children who can be transplanted and in each case donor organs are used for functional surgery designed for functional surgery. Penicillamine treatment was continued against implants in a patient with Wilson's disease because he could no longer meet the conditions prescribed by Sterneib. 18 The patient's ascites were gradually resolved and her serum albumin level and prothrombin duration were adjusted. Diagnosis. Another affected person with congenital hepatic fibrosis has developed portal hypertension, has had a

portosystemic shunt attack and the symptom is unaffected [33].

Direct communication with families was essential for a full psychological and social assessment and informed consent. Gold et al [9] highlighted the psychological and social pressures they face when using families during transplantation. Such criticism led to low expectations of problems in order to provide optimal performance. Informed consent from parents is required and long meetings are required. The decision to refuse the application was painful for 5 families. Some are afraid to stay in the hospital too long and the pain may be gone. Relatives no longer had to travel from Mexico to the United States. One teenage girl refused because of the fact that, regardless of the size of the liver lymphangioma, she believed that it had a purpose. If families stand firm in their decision to reject the re-transplant after discussion to clarify these issues, their choice becomes desirable. However, they had the option to change their brain, as did the families. Only through direct non-public communication can psychological and social assessments and informed consent be obtained [33].

Anatomical abnormalities that prevent effective implants were found in 5 patients. In all cases, the joint of the spleen and the developed mesenteric arteries have been too small to facilitate implantation. One in 5 patients has a situs inversus with a preduodenal portal vein, anatomically, which can no longer facilitate orthotopic implants [33].

All five patients survived surgery and all five remained HB5Ag after implantation. Two out of five patients died and postmortem tests showed evidence of ongoing active hepatitis. Others suffer from chronic hypertransaminoemia, despite a change in etiology to suspicious. The liver of the fifth affected person functioned normally. Effective efforts have been made to eradicate hepatitis B virus infection with hepatitis B hyperimmune immunoglobulin, which may further reduce the risk of HB8Ag recurrent active hepatitis B. Despite the fact that each of these conditions can increase the risk of liver transplantation, the decision to implant in such a patient is highly dependent on the availability and competition of donor organs [33].

The contraindications we have seen are self-explanatory. While very dangerous conditions may not prevent recurrence, there are scientific

cases that can cause headaches or high mortality. For example, people who were hospitalized or unconscious in an intensive care unit had an unusually high mortality rate of 60%. Surgical treatment of a patient with a portal vein thrombosed may be effective if the junction of the splenic and superior mesenteric arteries is large enough to allow portal vein insertion. Previous hepatobiliary surgery interventions would make reconstructive surgery difficult due to excessive adhesion. The length of a small patient is difficult to operate due to the need for small vascular anastomoses; However, over time, the experience and talent of an artificial doctor may become a major obstacle. Although there were no hepatitis B antigen strains in our series, the presence of soil hepatitis B antigen (Hb Ag) may be associated with a recurrence of the disease, noted in five adult Hb8Ag-induced liver transplants [33].

The additional need for organ donation is indicated by the 41 patients who died before transplantation. Orthopedics and specialist awareness centers are aimed at adults and there is little interest in organ donation. Because of the limited organs available, we have made the unwise decision not to prescribe implants in pediatric patients with advanced liver disease that is not related to abnormal metabolic processes. This decision stemmed from our love for the use of unusual resources from donated organs. Level in liver cancer transplant the first number is negative by only 3 [33].

9. SUMMARY AND CONCLUSION

It is said that the survival rate for children under one year of age or weighing less than 10 kg is usually between 65% and 80%, which was better compared to the 50-60% mentioned above. Examination requests have determined the survival rate of the most affected person after three months. Developing these recipients is the ultimate result of technological advancement, better connectivity education, and prevention of life-threatening and connective tissue disorders such as hepatic artery thrombosis and the first number of disorders.

Type of Donor: Donor factors affecting patient and donor survival include the donor's age of 50 years, but some studies have shown that older donors can be fully utilized. The effect on the type of connection (complete, low, delivery or live donor) is unclear. Within the distributed registry, whole-body recipients had fewer

survivors, dispersed, or better people affected and grafts than those living in allograft donors. A review of the U.S. Medical Registration Website of implanted patients found that there are more patients.

Diagnosis: Postoperative recovery is similar in patients with cholestatic and metabolic disorders. Early survival is worse for patients with severe liver failure and liver transplants, but their longevity is similar to that of other recipients. It is associated with the failure of more than one organ and the time to get a limited limb can affect this end result. Similar cases of drop in survival were observed in patients with PELD scores > 20, prominent recipients 1, and severe PELD scores prior to transplantation.

CONSENT

It is not applicable.

ETHICAL APPROVAL

It is not applicable.

ACKNOWLEDGEMENT

I would like to thank DR such an experience I would like to thank DR AHMED MEGAHED the supervisor of this paper for his efforts throughout the semester. I would like also to thank the MMMP staff for their support and allowing us to gain such an experience.

COMPETING INTERESTS

Authors have declared that no competing interests exist.

REFERENCES

1. Barbeta A, Butler C, Barhouma S, Hogen R, Rocque B, Goldbeck C, Schilperoort H, Meeberg G, Shapiro J, Kwon YK, Kohli R, Emamaullee J. *Transplant Direct.* 2021;7(10):e767. DOI: 10.1097/txd.0000000000001219
2. Berg CL, Merion RM, Shearon TH, Olthoff KM, Brown RS Jr, Baker TB, Everson GT, Hong JC, Terrault N, Hayashi PH, Fisher RA, Everhart JE. *Hepatology.* 2021;54(4):1313-21. DOI: 10.1002/hep.32143
3. Braun HJ, Dodge JL, Grab JD. *Live Donor Liver Transplantation in the United States: Impact of Share 35 on Live Donor Utilization. Transplantation.* 2021;105(4):824-831. DOI: 10.1097/tp.0000000000003318.
4. Broering DC, Elsheikh Y, Shagrani M, Abaalkhail F, Troisi RI. *Pure Laparoscopic Living Donor Left Lateral Sectionectomy in Pediatric Transplantation: A Propensity Score Analysis on 220 Consecutive Patients. Liver Transpl.* 2018;24(8):1019-1030. DOI: 10.1002/lt.25043.
5. Chan KM, Lee CF, Wu TJ, Chou HS, Yu MC, Lee WC, Chen MF. *Adverse outcomes in patients with postoperative ascites after liver resection for hepatocellular carcinoma. World J Surg.* 2012;36(2):392-400. DOI: 10.1007/s00268-011-1367-1.
6. Chan KM, Wang YC, Wu TH, Cheng CH, Lee CF, Wu TJ, et al. *Encouraging Split Liver Transplantation for Two Adult Recipients to Mitigate the High Incidence of Wait-list Mortality in The Setting of Extreme Shortage of Deceased Donors. Journal of clinical medicine.* 2019;8(12):2095. Available: <https://doi.org/10.3390/jcm8122095>
7. Chang CH, Bryce CL, Shneider BL. *Accuracy of the Pediatric End-stage Liver Disease Score in Estimating Pretransplant Mortality Among Pediatric Liver Transplant Candidates. JAMA Pediatrics.* 2018;172(11):1070-1077. DOI: 10.1001/jamapediatrics.2018.2541.
8. Cherukuru R, Reddy MS, Shanmugam NP, Rajalingam R, Kota V, Gunasekaran V, Narasimhan G, Kaliamoorthy I, Rela M. *Liver Transpl.* 2019;25(3):450-458. DOI: 10.1097/tp.0000000000001472
9. Cuenca AG, Yeh H. *Improving Patient Outcomes Following Pediatric Liver Transplant: Current Perspectives. Transplant Research and Risk Management.* 2019;11:69-78. Available: <https://doi.org/10.2147/TRRM.S183382>
10. Dalal AR. *Split liver transplantation: what's unique? World J Transplant.* 2015;5(3):89-94. DOI: 10.5500/wjt.v5.i3.89.
11. Feier F, Antunes E, D'Agostino D, VarelaFascinetto G, Jarufe N, Patillo JC, Vera A, Carrasco F, Kondo M, Porta G, Chapchap P, Seda-Neto J. *Pediatric liver transplantation in Latin America: where do*

- we stand? *Pediatr Transplant.* 2016;20(3):408-16.
DOI: 10.1111/ptr.12679.
12. Gavriilidis P, Roberts KJ, Azoulay D. Right lobe split liver graft versus whole liver transplantation: A systematic review by updated traditional and cumulative meta-analysis. *Dig Liver Dis.*2018;;50(12):1274-1282.
DOI: 10.1016/j.dld.2018.08.025.
 13. Guo CB, Pu CL, Li YC, Zhang MM, Deng Y, Yan LN, Kang Q, Jin XQ. Thirty-five consecutive pediatric living donor liver transplantation: experiences and lessons learned from a single center. *Hepato-gastroenterology.* 2014;61(130):391-7.
PMID: 24901148.
DOI: 10.1016/j.pcl.2017.02.003
 14. Hackl C, Schmidt KM, Süsal C, Döhler B, Zidek M, Schlitt HJ. *World J Gastroenterol.* 2018;24(47):5312-5321.
DOI: 10.3748/wjg.v24.i47.5312
 15. Hsu EK, Mazariegos GV. *Liver Transpl.* 2017;23(1):86-95.
DOI: 10.1002/lt.24646
 16. Khemichian S, Kahn J, Terrault NA. Use of Hepatitis B Virus-Positive Organs in Organ Transplantation. *Clin Liver Dis.* 2021;25(4):841-857.
DOI: 10.1016/j.cld.2021.06.009.
 17. Kim SH, Lee EC, Shim JR, Park SJ. A simplified protocol using rituximab and immunoglobulin for ABO-incompatible low-titre living donor liver transplantation. *Liver Int.* 2017;;38(5):932-939.
DOI: 10.1111/liv.13614.
 18. Kimura K, Yoshizumi T, Itoh S, Harimoto N, Motomura T, Harada N, Nagatsu A, et al. Efficacy of recombinant thrombomodulin for DIC after deceased donor liver transplantation: a case report. *Surgical case reports.* 2016;2(1):81.
Available:https://doi.org/10.1186/s40792-016-0208-8
 19. Lauterio A, Di Sandro S, Concone G, De Carlis R, Giacomoni A, De Carlis L. Current status and perspectives in split liver transplantation. *World J Gastroenterol.* 2015;21(39):11003-15.
DOI: 10.3748/wjg.v21.i39.11003.
 20. Mogul DB, Perito ER, Wood N. Impact of Acuity Circles on Outcomes for Pediatric Liver Transplant Candidates. *Transplantation.* 2020;;104(8):1627-1632.
DOI: 10.1097/tp.0000000000003079.
 21. Parmar A, Vandriel SM, Ng VL. Health-related quality of life after pediatric liver transplantation: A systematic review. *Liver Transplantation: Official Publication of the American Association for the Study of Liver Diseases and the International Liver Transplantation Society.* 2017;23(3):361-374.
DOI: 10.1002/lt.24696. PMID: 28006876.
 22. Pearson T, Zimmerman MA, Kim J, Palines PA, Eriksen CM, et al. Staged Biliary Reconstruction after Orthotopic Liver Transplantation: A Practical Surgical Strategy for High-Acuity Adult Recipients. *Transplantation direct.* 2019;5(9):e482.
Available:https://doi.org/10.1097/TXD.0000000000000924
 23. Pham YH, Miloh T. Liver Transplantation in Children. *Clin Liver Dis.* 2018;22(4):807-821.
DOI: 10.1016/j.cld.2018.06.004.
 24. Rana A, Pallister Z, Halazun K, Cotton R, Guiteau J, Nalty CC, O'Mahony CA, Goss JA. Pediatric liver transplant center volume and the likelihood of transplantation. *Pediatrics.* 2015;;136(1):e99-e107.
DOI: 10.1542/peds.2014-3016.
 25. Rawal N, Yazigi N. Pediatric Liver Transplantation *Pediatr Clin North Am.* 2017;; 64(3):677-684.
DOI: 10.1016/j.pcl.2017.02.003.
 26. Raza MH, Kim MH, Ding L. Long-Term Financial, Psychosocial, and Overall Health-Related Quality of Life After Living Liver Donation. *The Journal of Surgical Research.* 2020;253:41-52.
DOI: 10.1016/j.jss.2020.03.025.
 27. Saba P, Belfast E, Melnyk R, Patel A, Kashyap R, Ghazi A. Development of a High-Fidelity Robot-Assisted Kidney Transplant Simulation Platform Using Three-Dimensional Printing and Hydrogel Casting Technologies. *J Endourol.* 2020; 34(10):1088-1094.
DOI: 10.1089/end.2020.0441.
 28. Sandhu L, Sandroussi C, Guba M. Living donor liver transplantation versus deceased donor liver transplantation for hepatocellular carcinoma: comparable survival and recurrence. *Liver Transplantation : Official Publication of the American Association for the Study of Liver Diseases and the International Liver Transplantation Society.* 2012;;18(3):315-322.
DOI: 10.1002/lt.22477.
 29. Schonder KS, Mazariegos GV, Weber RJ. *Paediatr Drugs.* 2010;12(1):35-49.

- DOI:10.2165/11316180-000000000-00000.
30. Seehofer D, Eurich D, Veltzke-Schlieker W, Neuhaus P. Biliary complications after liver transplantation: old problems and new challenges. *Am J Transplant.* 2013; 3(2):253-65.
DOI: 10.1111/ajt.12034.
 31. Semer NB Awaiting liver transplantation. *Transplantation.* 2015;99(7):e48.
DOI: 10.1097/TP.0000000000000755.
 32. Wan P, Li Q, Zhang J, Xia Q. Right lobe split liver transplantation versus whole liver transplantation in adult recipients: A systematic review and meta-analysis. *Liver Transpl.* 2015;21(7):928-43.
DOI: 10.1002/lt.24135.
 33. Zamora-Valdes D, Leal-Leyte P. Fighting Mortality in the Waiting List: Liver Transplantation in North America, Europe, and Asia. *Ann Hepatol.* 2017;16(4):480-486.
Available: <https://www.medigraphic.com/cgi-bin/new/resumenI.cgi?IDARTICULO=75283>

© 2021 Elsaka et al.; This is an Open Access article distributed under the terms of the Creative Commons Attribution License (<http://creativecommons.org/licenses/by/4.0>), which permits unrestricted use, distribution, and reproduction in any medium, provided the original work is properly cited.

Peer-review history:
The peer review history for this paper can be accessed here:
<https://www.sdiarticle5.com/review-history/80066>