



Association of Clinicopathological Features with Lymph Node Metastasis: A Cross Sectional Study of Oral Squamous Cell Carcinoma Patients

**Fizza Abidi^{1*}, Mervyn Hosein², Saima Akram Butt¹, Abeeha Batool Zaidi³,
Angbeen Anjum¹ and Sana Fatima¹**

¹Department of Oral Pathology, Ziauddin College of Dentistry, Ziauddin University, Karachi, Pakistan.

²Ziauddin College of Dentistry, Ziauddin University, Karachi, Pakistan.

³Department of Community Dentistry, Ziauddin College of Dentistry, Ziauddin University, Karachi, Pakistan.

Authors' contributions

This work was carried out in collaboration among all authors. Author FA designed the study, wrote the protocol and wrote the first draft of the manuscript. Authors MH and SAB managed the analysis of the study. Author ABZ had performed data entry, statistical analysis and result write up. Authors AA and SF managed the literature searches. All authors read and approved the final manuscript.

Article Information

DOI: 10.9734/JAMMR/2020/v32i230365

Editor(s):

(1) Dr. Nurhan Cucer, Prof., Department of Medical Biology, Erciyes University, Faculty of Medicine, 38039, Kayseri, Turkey.

Reviewers:

(1) Deepak Sethi, Rabindra Nath Tagore Medical College, India.

(2) S. J. Carlan, USA.

Complete Peer review History: <http://www.sdiarticle4.com/review-history/54793>

Received 12 December 2019

Accepted 19 February 2020

Published 25 February 2020

Original Research Article

ABSTRACT

Aims: The aim of this study is to determine association between lymph node metastasis and various clinico-pathological parameters in order to predict their future prognosis of cancer patients.

Study Design: Cross sectional study design.

Place and Duration of Study: Ziauddin Hospital, North Nazimabad campus, Karachi.

Methodology: November 2018 to September 2019.

Results: The present study enrolled 140 OSCC patients visiting Ziauddin University of which 30 (21.4%) were females and 110 (78.6%) were male patients. The mean age of patients was 46.99 ± 12.26 . The buccal mucosa was the most common site observed 93 (66.4%). The mean size of tumour was 4.05 ± 2.261 mm, mean thickness was 1.70 ± 1.32 mm. It was found that lymph node metastasis was not present in 66 (47.1%) of OSCC cases, 22 (15.7%) cases were found N1, 9(6.4%) N2a, 27(19.3%) N2b, 3 (2.1%) and 13(9.3%) N3.

*Corresponding author: E-mail: dentistrulz12@gmail.com;

Significant association was found between age and lymph node metastasis: (P 0.02); however, gender showed no significant association. (P 0.149). Thickness of tumor, site of tumor, peri-neural invasion, lympho-vascular invasion and bone penetration showed significant association with lymph node metastasis with (P 0.040, 0.021, 0.016, 0.00 and 0.001) respectively.

Conclusion: Our study showed significant association of lymph node involvement with tumour staging, tumour thickness, lymphovascular involvement, perineural invasion and bone penetration. Our suggestion is to incorporate these clinic-pathological variables while determining the treatment and prognosis of Oral squamous cell Carcinoma (OSCC). Given the very high incidence and prevalence of Oral Cancer in our country and the region further multi-centered researches should be carried out and with larger sample sizes. Early diagnosis and restrictions on smokeless tobacco products can limit the occurrence and progression of OSCC.

Keywords: Oral; squamous cell carcinoma; lymph node; metastasis.

1. INTRODUCTION

The term oral cancer refers to head and neck neoplasms arising from the oral cavity and oropharyngeal region; almost 90% are squamous cell carcinoma of the oral cavity. Globally, oral cancer is the 6th most frequently diagnosed cancer with a high incidence and prevalence rate, increasing yearly in many countries [1].

The worldwide prevalence of oral cancer is about 2% to 4%. Whereas in Pakistan it is about 10% and in Indian population it is up to 40 % [2]. Oral cancer is emerging as the major health problem and a leading cause of death in Asian countries. It is predicted that the number of new cases in Asia in 2020 will rise to 7.1 million which is alarming, in spite of all the treatment and preventive cancer strategies [3,4].

Advancements in oral cancer treatment modalities have not significantly improved the mortality rate among cancer patients over the last few decades. In spite of the easy access of oral cavity for clinical evaluation, Oral squamous cell carcinomas (OSCC) usually is diagnosed in advanced disease stages. The reasons for incorrect diagnosis include patient reluctance for appropriate treatment and physician negligence [2,5]. Oral cancer prognosis has not improved in the last few decades and therefore accurate diagnosis and early detection is critical [6]. Oral squamous cell carcinomas (OSCC) have a greater tendency to metastasize through lymphatics rather than haematogenous spread, so the status and management of the neck is mandatory in the treatment planning of OSCC patients. The prognostic factors of utmost importance in cancer patients's survival is the diagnosis of lymph node metastasis [7]. The 5-year survival rate for Oral squamous cell carcinomas patients with metastasis is 45-50% [6,8-10].

Occult metastasis is the utmost important and significant marker for the early and late management of the neck surgeries. However, the rate of occult metastasis in cervical lymph node status is about 20 to 30% so this should be analyzed accurately [11]. Now a days for the correct diagnosis of occult metastasis ultrasound guided fine needle aspiration cytology, Computed Tomography(CT)scan, Magnetic Resonance Imaging (MRI), Positron Imaging Tomography (PET scans), imaging techniques have been used [12].

Literature suggested that in OSCC patients if lymph node metastasis is present occult metastasis will occur in 80% cases, In these cases neck dissection will need to be performed with appropriate lymph node clearance. Now days, in order to reduce mortality and morbidity of radical neck dissection, Selective neck dissections are applied [2]. The purpose of lymph node status assessment in oral cancer patients is to select an appropriate treatment along with patient survival. Therefore a thorough understanding of the process of lymphatics metastasis is necessary for a better clinical diagnosis and treatment [10].

Oral cancers are potentially highly aggressive lesions because they can metastasize to the regional lymph nodes as well as infiltrate into the surrounding peri-oral tissue [13]. In OSCC lymph node metastasis is the most foremost prognostic feature and is associated with tumor relapse and shorter survival rate. Depth of invasion of tumor is the most important variant to predict occult metastasis. Depth of invasion between 2 to 5 mm is an indication for elective node dissection [14]. When there is a nodal involvement in oral cancer neck dissection along with tumor removal is indicated, Lymph node excisional biopsies have been performed before neck dissection in primary oral cancer cases. Authentic, accurate,

reporting of the lymph node status and tumor descriptive elements are the basic prerequisites for the clinician in order to determine the proper staging and grading of the tumor [15].

The aim of this study is to determine association between lymph node metastasis and various clinico-pathological parameters in order to predict their future prognosis of cancer patients.

2. MATERIALS AND METHODS

This was a Cross Sectional study; ethical approval was obtained from Ziauddin University Ethics Review Committee (Reference Code: 0330618FAOM) prior to conducting research. Informed consent was taken from patients/guardians, visiting Ziauddin Hospital, North Nazimabad campus, for giving oral cancer biopsies between November 2018 to September 2019. 140 samples of OSCC and their histopathological reports had been obtained. The sampling technique is consecutive.

The following variables were recorded Patients' age, gender, size, thickness and site of tumor: as lesion involving buccal mucosa, tongue. The collected biopsy specimens were fixed in 10% formalin, embedded in paraffin. H & E staining was performed. Grading was done by using protocols set by WHO (Broder system) and staging was assessed by using the AJCC classification (TNM classification). Perineural invasion, lympho-vascular invasion, dysplasia, bone and muscle invasion were also recorded.

2.1 Statistical Analysis

SPSS (v.21.0) was used for statistical analysis. Data for categorical variables were expressed in frequencies and percentages. Kolmogorov-Smirnov test was used to check normality of data. Chi-square test was used to find the association between lymph node metastasis and different clinical and histopathological parameters. Kruskal-Wallis test was used to find association between lymph node metastasis and tumor size and thickness. ANOVA was used to find association between lymph node metastasis and age of patients. P-value less than 0.05 were regarded statistically significant.

3. RESULTS

The present study enrolled 140 OSCC patients visiting Ziauddin hospital of which 30 (21.4%) were females and 110 (78.6%) were male patients. The mean age of patients was 46.99 ± 12.26 . The buccal mucosa was the most common site observed 93 (66.4%). The second common site in our patients was the lateral border of tongue 18 (12.9%) (Fig. 1).

The mean age of our sample was 46.99 ± 12.36 years, mean size of tumour was 4.05 ± 2.261 mm, mean thickness was 1.70 ± 1.32 mm. It was found that lymph node metastasis was not present in 66 (47.1%) of OSCC cases, 22 (15.7%) cases were found N1, 9(6.4%) N2a, 27(19.3%) N2b, 3 (2.1%) and 13(9.3%) N3 (Table 2).

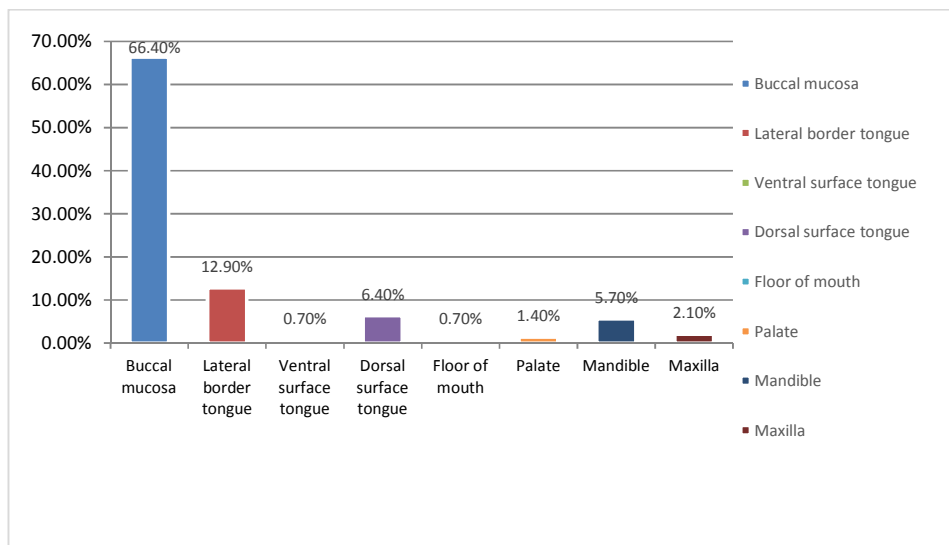


Fig. 1. Squamous cell carcinoma anatomical sites

Table 1. Association of lymph nodes with invasions, dysplasia, muscle and bone invasion

		N0 n (%)	N1 n (%)	N2a n (%)	N2b n (%)	N2c n (%)	N3 n (%)	Total n=140	p-value
Peri-neural invasion	Yes	10 (31.3%)	6(18.8%)	2(6.3%)	5(15.6%)	1(3.1%)	8(25%)	32	0.016*
	No	56(51.9%)	16(14.8%)	7(6.5%)	22(20.4%)	2(1.9%)	5(4.6%)	108	
Lympho-vascular invasion	Yes	-	-	1(14.3%)	-	-	6(85.7%)	7	0.00*
	No	66(49.6%)	22(16.5%)	9(6.8%)	26(19.5%)	3(2.3%)	7(5.3%)	133	
Muscle Invasion	Yes	37(44%)	13(15.5%)	4(4.8%)	17(20.2%)	3(3.6%)	10(11.9%)	84	0.41
	No	29(5.8%)	9(40.9%)	5(2.9%)	10(17.9%)	-	3(5.4%)	56	
Bone Invasion	Yes	32(42.7%)	7(9.3%)	8(10.7%)	13(17.3%)	3(4%)	12(16%)	75	0.001*
	No	34(52.3%)	15(23.1%)	1(1.5%)	14(21.5%)	-	1(1.5%)	65	
Dysplasia	Yes	5(62.5%)	1(12.5%)	-	2(25%)	-	-	8	0.83
	No	61(46.2%)	21(15.9%)	9(6.81%)	25(18.9%)	3(2.3%)	13(9.8%)	132	

*Significant <0.05; χ^2 test was used

Significant association was found between age and lymph node metastasis: (*P* 0.02); however, gender showed no significant association (*P* 0.149).

Thickness of tumor, site of tumor, peri-neural invasion (Table 1), lympho-vascular invasion and bone invasion (Table 1) showed significant association with lymph node metastasis with (*P* 0.040, 0.021, 0.016, 0.00 and 0.001) respectively.

Whereas size of tumor, tumor grade (Table 3), histological type, degree of dysplasia (Table 1) and muscle invasion showed no significant association with lymph node metastasis with (*P* 0.171, 0.995, 0.830 and 0.417) respectively.

4. DISCUSSION

Many studies have emphasized that oral squamous cell carcinoma constitutes up to 80 to 90 percent of all malignancies [16].

Evaluation of histological parameters in OSCC invasion is determined by penetration of tumor into lymphatics, blood vessels, perineural involvement and grading. The TNM classification was used for assessing the clinical significance and importance of these clinicopathological parameters in order to evaluate the tumor aggressiveness [17]. Our study showed that OSCC was more common in male patients 110

(78.6%) as compared to the female patients 30 (21.4%)The mean age of our sample was 46.99 ± 12.36 years which was consistent with the literature reviewed as most cases have been reported in middle and older age groups [5,9,18, 19].

The buccal mucosa was the most common site observed, 93 (12.9%). The second common site was the lateral border of tongue: 18 (12.9%) which corroborated with other studies. In our study buccal mucosa was the common site followed by tongue for the developing of oral cancer which were consistent with other studies. In countries of South East Asia the use of smokeless tobacco, areca nut and betel quid were very much prevalent in population due to cultural habits use of such deleterious substances causes exposure of buccal mucosa to carcinogenic substances increasing the susceptibility of having cancer [5,8,19,20]. In west the most common site of oral cancer is tongue due to smoking and alcohol consumption Thus we can conclude that change of habits plays an important part in development of oral squamous cell carcinoma globally [21,22].

Several studies showed tumour size were associated with lymph node involvement [5,23]. But disparity exist in literature The mean size of tumour was 4.05 ± 2.261 mm which showed no association with lymph node metastasis *P* 0.171 and was in accordance with some researches [20,24,25].

Table 2. Association of lymph node involvement with tumor stage (n=140)

Lymph nodes	T1 n(%) n=21	T2 n (%) n=40	T3 n (%) n=26	T4 n (%) n=53	Total n=140
N0	15(22.7%)	19(28.8%)	11(16.7%)	21(31.8%)	66(100%)
N1	3 (13.6%)	11(50%)	2(9.1%)	6(27.3%)	22(100%)
N2a	1(11.1%)	-	1(11.1%)	7(77.8%)	9(100%)
N2b	2(7.4%)	7(5.9%)	9(33.3)	9(33.3%)	27(100%)
N2c	-	1(33.3%)	-	2(66.7%)	3(100%)
N3	-	2(15.4%)	3(23.1%)	8(61.5%)	13(100%)
p- value	0.035*				

*Significant at <0.05; χ2 test was used

Table 3. Association of lymph node involvement with tumor grade (n=140)

Lymph nodes	G1n(%) n=13	G2n(%) n=119	G3n(%) n=8	Total n=140
N0	8(12.1%)	57(86.4%)	1(1.5%)	66(100%)
N1	1(4.5%)	19(86.4%)	2(9.1%)	22(100%)
N2a	1(11.1%)	6(66.7%)	2(22.2%)	9(100%)
N2b	3(11.1%)	22(81.5%)	2(7.4%)	27(100%)
N2c	-	3(100%)	-	3(100%)
N3	-	12(92.3%)	1(7.7%)	13(100%)
P value	0.401			

*Significant at <0.05; χ2 test was used

The mean thickness of tumour was 1.70 ± 1.32 cm which were significantly associated with lymph node metastasis (P 0.040) in accordance with other studies [5,26]. The cut off value for tumour thickness is 4 mm [27,28]. At this cut off point the chances of nodal metastasis increases upto 20%, with a 50% decrease in survival rate [29,30].

Patients without nodal involvement have a better survival rate of 60 to 70% as compared with known nodal metastasis [31].

It was found that lymph node metastasis was present in 74 (52.8%) OSCC which was consistent with other literature. However, in tumour Staging, Stage II and Stage IV were most common. The most common nodal stage was N0 [5,9,31,32].

Peri-neural invasion (P 0.016), showed significant association with lymph nodal involvement which is consistent with some studies [24,33]. Perineural invasion is associated with an increase in death rate in OSCC. It can be used as prognostic indicator [34] which is contrary to some studies [35].

Our studied showed 89% moderately differentiated Oral squamous cell carcinomas cases (Table 3) which were comparable with other study conducted in Karachi in which more than half of the patients were moderately differentiated Oral Squamous Cell carcinomas cases of the oral cavity [9].

As our study has showed significant association between lymphovascular invasion, bone penetration, tumor staging with lymph node metastasis but there is not enough evidence to support this finding. However regional recurrence of tumor does not affect the lymphovascular invasion [33].

The size of tumor, tumor grade, histological type, degree of dysplasia and muscle penetration showed no significant association with lymph node metastasis due to the limited number of cases and required studies conducted with larger sample size [5,36].

5. CONCLUSION

Our study showed significant association of lymph node involvement with tumour staging, tumour thickness, lymphovascular involvement, perineural invasion and bone penetration. Our

suggestion is to incorporate these clinic-pathological variables while determining the treatment and prognosis of OSCC. Given the very high incidence and prevalence of Oral Cancer in our country and the region further multi-centered researches should be carried out and with larger sample sizes. Early diagnosis and restrictions on smokeless tobacco products can limit the occurrence and progression of OSCC.

6. LIMITATIONS

The limitation of this study was smaller sample size and this study contains population of Karachi only from one centered It should be done multicentered with larger sample size in order to represent the Pakistani population.

CONSENT

Written Inform consent was taken from patients/Guardians.

ETHICAL APPROVAL

Ethical approval was obtained from Ziauddin University Ethics Review Committee (Reference Code: 0330618FAOM).

ACKNOWLEDGEMENTS

I would like to thank Dr Adnan Zuberi and Department of Histo pathology Ziauddin Hospital North Nazimabad, Department of Oral Pathology Ziauddin College of Dentistry for their co-operation and assistance.

COMPETING INTERESTS

Authors have declared that no competing interests exist.

REFERENCES

1. Chang S-CL, We-Ling Chang, Yin-Fan Lee, ChihTing Wu, Jin-Shang,Hsu, Pang-Hung, Chang, Chuan Fa. Glycoproteomic identification of novel plasma biomarkers for oral cancer. *Journal of Food and Drug Analysis*. 2019;27(2):483-93.
2. Markopoulos. Current aspects on oral squamous cell carcinoma. *The Open Dentistry Journal*. 2012;6:126.
3. Hanif MZ, Parveen. Institution-based cancer incidence in a local population in Pakistan: Nine year data analysis. *Asian Pac J Cancer Prev*. 2009;10(2):227-30.

4. Park SB. Aetiology of cancer in Asia. *Asian Pac J Cancer Prev.* 2008;9(3):371-80.
5. Sana Mirza NIH, Saima Akram, Noor-ul-Wahab, Zohaib Akram. Histopathological predictors of nodal metastases in oral squamous cell carcinoma. *PJMD.* 2016;5(03):12-6.
6. Yakob M, Fuentes L, Wang M, Abemayor E, Wong D. Salivary biomarkers for detection of oral squamous cell carcinoma: Current state and recent advances. *Curr Oral Health Rep.* 2014;1:133-41.
7. de Bree R. Elective neck dissection in oral squamous cell carcinoma: Past, present and future. *Oral Oncology.* 2019;90:87-93.
8. Aziz MU, Shahzad S, Mahmood S. Radiological patterns of head and neck cancers in Karachi: A clinical audit. *PJR.* 2016;23(1).
9. Alamgir MM, Jamal Q, Mirza T. Conventional clinical and prognostic variables in 150 oral squamous cell carcinoma cases from the indigenous population of Karachi. *Pakistan Journal of Medical Sciences.* 2016;32(3):672.
10. Chen YL, Wu WL, Jang CW, Yen YC, Wang SH, Tsai FY, et al. Interferon-stimulated gene 15 modulates cell migration by interacting with Rac1 and contributes to lymph node metastasis of oral squamous cell carcinoma cells. *Oncogene;* 2019.
11. Mølstrøm J, Grønne M, Green A, Bakholdt V, Sørensen JA. Topographical distribution of sentinel nodes and metastases from T1–T2 oral squamous cell carcinomas. *European Journal of Cancer.* 2019;107:86-92.
12. Leusink FK, Koudounarakis E, Frank MH, Koole R, van Diest PJ, Willems SM. Cathepsin K. Associates with lymph node metastasis and poor prognosis in oral squamous cell carcinoma. *BMC Cancer.* 2018;18(1):385.
13. Baig MS, Bhutto RA, Muhammad S, Siddiqui MI. Epidemiology of oral cancer in Southern Punjab, Pakistan. *Pak J Med Heal Sci.* 2015;9:1269-71.
14. Bur AM, Holcomb A, Goodwin S, Woodroof J, Karadaghy O, Shnayder Y, et al. Machine learning to predict occult nodal metastasis in early oral squamous cell carcinoma. *Oral Oncology.* 2019;92:20-5.
15. Bullock MJ. Data set for the reporting of nodal excisions and neck dissection specimens for head and neck tumors: Explanations and recommendations of the guidelines From the International Collaboration on Cancer Reporting (ICCR). *Archives of Pathology & Laboratory Medicine;* 2018.
16. Pires FRR AB, Oliveira JB, Tavares AS, Luz PS, Santos TC. Oral squamous cell carcinoma: Clinicopathological features from 346 cases from a single oral pathology service during an 8-year period. *Journal of Applied Oral Science: Revista FOB.* 2013;21(5):460-7.
17. Safi AFG, Kathrin Drebber, Uta Schick, Volker Thiele, Oliver Backhaus, Tim Nickenig, Hans-Joachim Zöller, Joachim E. Kreppel, Matthias. A novel histopathological scoring system for patients with oral squamous cell carcinoma. *Clinical Oral Investigations.* 2019;1-7.
18. Akram S, Mirza T, Aamir Mirza M, Qureshi M. Emerging patterns in clinicopathological spectrum of oral cancers. *Pak J Med Sci.* 2013;29(3):783-7.
19. Zulfiqar G, Naqash MA, Tuz-Zahra F, Arshad T, Ahmad F, Khan SFA. A study on distribution of cervical lymph node metastases in oral squamous cell carcinoma (OSCC); 2017.
20. Bhurgri Y, Bhurgri A, Usman A, Pervez S, Kayani N, Bashir I, et al. Epidemiological review of head and neck cancers in Karachi. *Asian Pac J Cancer Prev.* 2006;7(2):195-200.
21. Warnakulasuriya S. Global epidemiology of oral and oropharyngeal cancer. *Oral Oncol.* 2009;45(4-5):309-16.
22. Mirza D, Raza G, Basit A, Naqvi K, Ahmed S, Abassi ZA. Oral Squamous Cell Carcinoma (OSCC) in Karachi city--A retrospective study. *Pakistan Oral & Dental Journal.* 2016;36(3).
23. Woolgar J, Rogers S, Lowe D, Brown J, Vaughan E. Cervical lymph node metastasis in oral cancer: The importance of even microscopic extracapsular spread. *Oral Oncology.* 2003;39(2):130-7.
24. Ghafari RN, Noushin Jalayer Razavi, Amirnader Emami. A retrospective institutional study of histopathologic pattern of Oral Squamous Cell Carcinoma (OSCC) in Tehran, Iran during 2006 - 2015. *Journal of Research in Medical Sciences.* 2019;2.
25. Abbas S, Saeed J, Tariq M, Baksh A, Hashmi S. Clinicopathological prognostic factors of oral squamous cell carcinoma: An experience of a tertiary care hospital.

- JPMA The Journal of the Pakistan Medical Association. 2018;68(7):1115.
26. Aslam F, Atique M, Aslam M, Sarfraz T, Ayaz BAB, Alamgir W. Relation of tumour thickness with lymph node metastasis in oral squamous cell carcinoma. Pakistan Armed Forces Medical Journal. 2012; 62(4):529-33.
 27. Zia S, Naqvi SU, Adel H, Adil SO, Hussain M. Relationship of Oral Tumor Thickness with the rate of lymph node metastasis in Neck based on CT Scan. Pakistan Journal of Medical Sciences. 2017;33(2): 353.
 28. Huang SH, Hwang D, Lockwood G, Goldstein DP, O'Sullivan B. Predictive value of tumor thickness for cervical lymph-node involvement in squamous cell carcinoma of the oral cavity: A meta-analysis of reported studies. Cancer: Interdisciplinary International Journal of the American Cancer Society. 2009;115(7): 1489-97.
 29. De Silva RK, Siriwardena BSMS, Samaranyaka A, Abeyasinghe WAMUL, Tilakaratne WM. A model to predict nodal metastasis in patients with oral squamous cell carcinoma. PloS One. 2018;13(8): e0201755-e.
 30. Liu B, Amaratunga R, Veness M, Wong E, Abdul-Razak M, Coleman H, et al. Tumor depth of invasion versus tumor thickness in guiding regional nodal treatment in early oral tongue squamous cell carcinoma. Oral Surgery, Oral Medicine, Oral Pathology and Oral Radiology; 2019.
 31. Shingaki S, Takada M, Sasai K, Bibi R, Kobayashi T, Nomura T, et al. Impact of lymph node metastasis on the pattern of failure and survival in oral carcinomas. The American Journal of Surgery. 2003;185(3): 278-84.
 32. Doshi NPS. Histological grading of oral cancer: A comparison of different systems and their relation to lymph node metastasis. National Journal of Community Medicine. 2011;2(1):136-42.
 33. Adel M, Kao HK, Hsu CL, Huang JJ, Lee LY, Huang Y, et al. Evaluation of lymphatic and vascular invasion in relation to clinicopathological factors and treatment outcome in oral cavity squamous cell carcinoma. Medicine. 2015;94(43).
 34. Hasmat S, Ebrahimi A, Gao K, Low TH, Palme C, Gupta R, et al. Multifocal perineural invasion is a better prognosticator than depth of invasion in oral squamous cell carcinoma. Head & neck. 2019;41(11):3992-9.
 35. Park J, Megow A, Swalling A, Hodge JC, Foreman A, Boase S, et al. Prognosis of oral squamous cell carcinoma with perineural invasion: A comparative study of classification types. Clinical Otolaryngology; 2019.
 36. Frare JC, Sawazaki-Calone I, Ana-Lucia-Carrinho Ayroza-Rangel A, Bueno G, de Moraes CF, Nagai HM, et al. Histopathological grading systems analysis of oral squamous cell carcinomas of young patients. Medicina Oral, Patologia Oral Y Cirugia Bucal. 2016;21(3):e285.

© 2020 Abidi et al.; This is an Open Access article distributed under the terms of the Creative Commons Attribution License (<http://creativecommons.org/licenses/by/4.0>), which permits unrestricted use, distribution, and reproduction in any medium, provided the original work is properly cited.

Peer-review history:

The peer review history for this paper can be accessed here:
<http://www.sdiarticle4.com/review-history/54793>