

## **High-degree Atrioventricular Block May be Associated with Basedow's Disease: A Case Report**

**N. Mahoungou-Mackonia<sup>1\*</sup>, Harouna Seydou<sup>1</sup>, Brahim Nassour<sup>1</sup>, Njei Malick<sup>1</sup>,  
Fadoul Adam<sup>1</sup>, Ovaga Esther<sup>1</sup>, I. Nouamou<sup>1</sup>, S. Arous<sup>1</sup>, G. Benouna<sup>1</sup>,  
A. Drighil<sup>1</sup>, L. Azzouzi<sup>1</sup> and R. Habbal<sup>1</sup>**

<sup>1</sup>*Department of Cardiology, IBN ROCHD University Hospital, Casablanca, Morocco.*

### **Authors' contributions**

*This work was carried out in collaboration among all authors. Author NMM designed the study, performed the statistical analysis, wrote the protocol, and wrote the first draft of the manuscript. Authors HS and BN managed the analyses of the study. Author NM managed the literature searches. All authors read and approved the final manuscript.*

### **Article Information**

#### Editor(s):

(1) Dr. Irina-Luliana Costache, "Gr. T. Popa" University of Medicine and Pharmacy, Romania.

#### Reviewers:

(1) Ana Paula Tagliari, University Hospital of Zurich, Switzerland.

(2) Yasser Mohammed Hassanain Elsayed, Egyptian Ministry of Health (MOH), Egypt.

Complete Peer review History: <http://www.sdiarticle4.com/review-history/62935>

**Case Study**

**Received 26 September 2020**

**Accepted 01 December 2020**

**Published 12 December 2020**

### **ABSTRACT**

It has been reported that hyperthyroidism could be the cause of arrhythmias at the ventricular and supraventricular levels, while conduction disorders are very rarely described. We report through our observation the case of a 45-year-old patient diagnosed with atrioventricular block (AVB) who, after exploration, showed Basedow's Disease. The patient was put on Carbimazole 40mg divided in two doses, which allowed to observe a complete regression of the AVB at the end of 2 months of treatment by passing by an alternation AVB 2-th degree mobitz 1 to mobitz 2 and a progressive improvement of the thyroid hormones until obtaining euthyroidism. Thyrotoxic myocarditis is the most likely cause of AVB, since in our patient no classical cause of AVB was found and the conductive disorder was evolving in parallel with hyperthyroidism, which allowed us to retain the diagnosis.

*Keywords: High-degree atrioventricular block; basedow's disease; hyperthyroidism.*

*\*Corresponding author: E-mail: maschellmahoungou@gmail.com;*

## 1. INTRODUCTION

Hyperthyroidism is the cause of many cardiac electrical abnormalities including sinus or atrial tachycardia, ventricular extrasystoles and ventricular repolarization abnormalities. Atrial fibrillation is common in hyperthyroidism adding a high emboligenic risk.

On the other hand, the mechanism of the effects of hyperthyroidism on the cardiac conduction system are not known with certainty [1]. Hyperthyroidism-related disorders remain rare (5 to 10%). They are mainly represented by atrioventricular blocks (AVB), the most frequent of which is the first degree block [2].

It is with this in mind that we report the case of hyperthyroidism revealed during high-grade AVB.

## 2. CASE REPORT

We are reporting the case of a 45 year old patient, chronic smoker at 25 packs/year, non-athletic and with no particular history, in particular, no notion of taking medication (antiarrhythmics, calcium channel blockers), who was admitted to the emergency room for dyspnea and dizziness.

His clinical examination showed a blood pressure of 140/90 mmHg, bradycardia with a heart rate of 35 beats/min with a strictly normal physical examination of the systems. An electrocardiogram (ECG) showed a complete AVB with an escape rate of 37 beats per minute.

A transthoracic ultrasound was performed but the result was within the limits of normal, in particular (good bi-ventricular function without disturbance of the kinetics, non-dilated atrial mass, no valvulopathy, no vegetation, no abscess or valvular tear). A biological evaluation was performed, including troponins which were negative as well as the infectious test : a normal procalcitonin at 0.18 ng/ml, a normal CRP at 2 mg/L as well as the CBC with a white blood cell count of 6880/mm<sup>3</sup>. A normal electrolyte balance: A kalemia of 4.7 mEq/l. On the other hand the metabolic, investigations showed hyperthyroidism with a T3L at 4.7 nmol/l (1.7-3.7) and a TSH at 0 mIU/L. The cervical ultrasound, revealed homogeneous increase in thyroid size, a thyroid scan showed a high uptake at the gland level suggesting Basedow's disease.

Finally, the diagnosis of metabolic AVB related to hyperthyroidism in the context of Basedow disease was retained. The patient was placed on synthetic carbimazole antithyroid medication at a dose of 20 mgx2/day. The patient was put on dimazole 20 mgx2/day and then was electro-stimulated with a temporary electrostimulation probe for two weeks. After a slight improvement of the thyroid test, T3L at 4mEq/l, the probe was removed, the heart rate oscillated between 45-50 beats/min with alternating BAV 2 nd ~~nd~~ degree Mobitz 1 to Mobitz 2.

The patient was discharged from the hospital with close follow-up. After two (2) months from the pharmacological treatment we noticed a complete regression of the AVB with a heart rate that had gone of 70 beats/min.

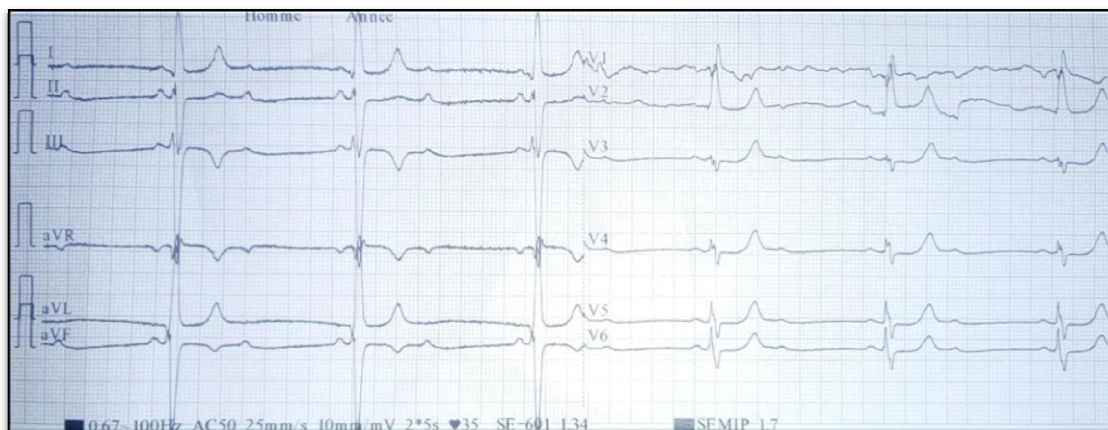
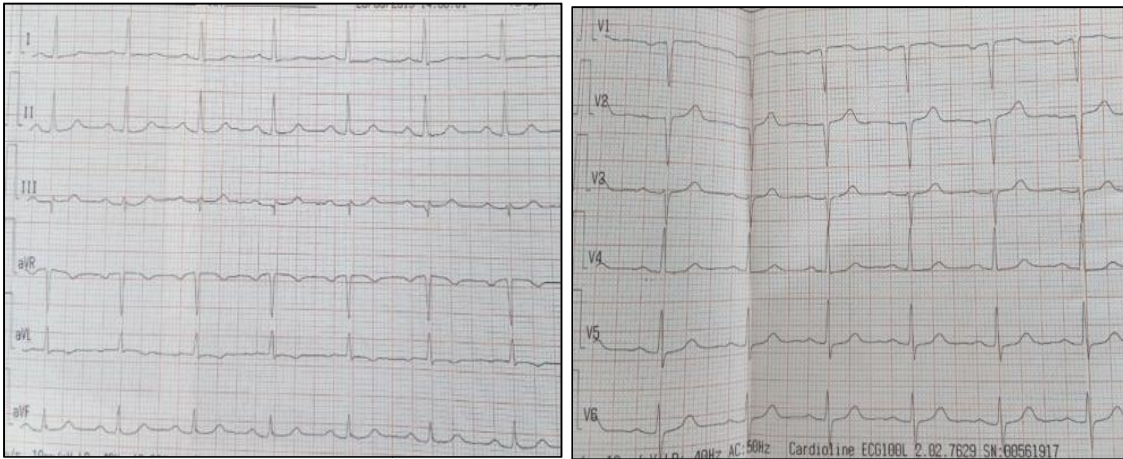


Fig. 1. 12-lead ECG performed in November 2019 in the Cardiovascular Intensive Care Unit, in a 45-year-old patient in high-degree atrioventricular block at 37 beats/minute



**Fig. 2. 12-lead ECG in a 45-year-old patient in sinus rhythm at 75 beats/minute at 02 months of treatment basedow's disease**

### 3. DISCUSSION

Hyperthyroidism is most often responsible for arrhythmias at the supraventricular or ventricular levels. Conductive disorders related to hyperthyroidism are very rarely described. We found in the literature, 6 documented observations. In 4 cases [3–6], it is a case of high degree AVB, in one case of 1st degree AVB [1] and the last case of sinus bradycardia [2]. In 2 cases, the subjects were young people under 50 years of age. Basedow's disease was found in most of these cases.

The existence of a conduction disorder during hyperthyroidism may be the result of a chance association. Indeed, for most observations, there are infectious or iatrogenic factors that may be responsible, on their own, for the occurrence of AVB [6]. The rapidly regressive evolution of the conductive disorder also confirms this hypothesis. In other cases, it is valvular, ischemic or degenerative heart disease [7]. Congenital block is more difficult to apprehend, it represents 3-5% of AVB [8], especially in the absence of previous ECG tracings; the persistence of the conductive disorder after correction of dysthyroidism would be in favor of this etiology. Cases with BAV where only thyrotoxicosis seems to be responsible for conductive disorders are exceptional. When this is the case, there is no particular terrain explaining AVB, and normalization of atrioventricular conduction occurs in parallel with the return to euthyroidism. Both autoimmune focal myocarditis and thyrotoxic myocarditis are responsible for the occurrence of AVB [2,9,10]. In 5 cases found in

the literature, sub-clinical or clinical hyperthyroidism with or without thyrotoxicosis was the sole cause of conduction disorders of the sinus dysfunction type. The sinus rhythm was rapidly observed in most cases after two weeks to one month on synthetic antithyroid drugs.

In our patient, no classical cause of AVB is reported and the conductive disorder evolves in parallel with the hyperthyroidism.

Our observation is in favor of a relationship between basedow's disease and AVB whose only mechanism of occurrence of AVB is thyrotoxicosis-induced myocarditis. Since 2 months after pharmacological treatment, the ultrasensitive TSH and T3L became normal, and AVB completely regressed.

### 4. CONCLUSION

The existence of AVB during hyperthyroidism is rare and in most cases, for the AVB to occur, there must be a causal condition that can damage the myocardium. The block usually regresses before the return to euthyroidism. Exceptionally, hyperthyroidism alone seems to be responsible for complete AVB. At the origin of these conductive disorders, thyrotoxic myocarditis and/or autoimmune mechanisms are evoked. Although rare, the possibility of such disorders in hyperthyroid subjects requires electrocardiographic monitoring, all the more rigorous in case of prescription of negative dromotropic drugs, and in particularly betablockers.

## CONSENT

In accordance with the international or academic standard, the patient's written consent has been collected and retained by the author(s).

## ETHICAL APPROVAL

It is not applicable.

## COMPETING INTERESTS

Authors have declared that no competing interests exist.

## REFERENCES

1. Celebi AS. Reversible first degree Atrioventricular Block Due To Hyperthyroidism. Arch Turk Soc Cardiol [Internet]; 2016. [Cité 29 oct 2020] Available:<http://archivestsc.com/jvi.aspx?un=TKDA-66179>
2. Moustaghfir A, Kharchafi A, Mahassin F, Chaari J, Ghafir D, Ohayon V, et al. Dysfonction sinusale au cours d'une maladie de Basedow. A propos d'une observation. La Revue de Médecine Interne. 1999;20(9):804-5.
3. Karakaş CY, Topaloğlu C, Canbolant E, Seyfeli E, Akgül F. Hyperthyroidism as a rare cause of complete AV block. Anadolu Kardiyol Derg. 2009;9(1):67-8.
4. Alper AT, Hasdemir H, Akyol A, Cakmak N. Subclinical hyperthyroidism presenting with bradycardia-associated syncope. West Indian Med J. 2008;57(2):173-4.
5. Amasyali B. Supra-His complete atrioventricular block in a patient with subclinical hyperthyroidism. Turk Kardiyol Dern Ars. 2011;39(8):693-6.
6. Kuo YC, Tseng YT, Lee TI, Hsieh MH. Chronic bifascicular block with intermittent complete atrioventricular block induced by hyperthyroidism. International Journal of Cardiology. 2006;110(3):407-10.
7. Auzou G, Brunat F, Clot S, Rocher T, Turck J, Maggio L, et al. Bloc auriculoventriculaire du troisième degré et infarctus du myocarde à la prise en charge initiale. Ann Fr Med Urgence. 2018;8(2): 89-93.
8. Collège des Enseignants de Cardiologie et Maladies Vasculaires. Troubles de la conduction intracardiaque. Université Médicale Virtuelle Francophone; 2011.
9. Archambeaud-Mouveroux F, Roussanne A, Jadaud J, Dejax C, Blanc P, Laubie B. [Prolonged hyperthyroidism and recurrent atrio-ventricular block]. Rev Med Interne. 1987;8(2):213-7.
10. Vilches AR, Lerman J. [First degree atrio-ventricular block in acute thyrotoxicosis]. Medicina (B Aires). 2004;64(1):51-3.

© 2020 Mahoungou-Mackonia et al.; This is an Open Access article distributed under the terms of the Creative Commons Attribution License (<http://creativecommons.org/licenses/by/4.0>), which permits unrestricted use, distribution, and reproduction in any medium, provided the original work is properly cited.

Peer-review history:

The peer review history for this paper can be accessed here:  
<http://www.sdiarticle4.com/review-history/62935>